



Original Research

# Cutaneous, gastrointestinal, hepatic, endocrine, and renal side-effects of anti-PD-1 therapy



Lars Hofmann<sup>a</sup>, Andrea Forschner<sup>b</sup>, Carmen Loquai<sup>c</sup>,  
Simone M. Goldinger<sup>d</sup>, Lisa Zimmer<sup>e</sup>, Selma Ugurel<sup>e</sup>,  
Maria I. Schmidgen<sup>c</sup>, Ralf Gutzmer<sup>f</sup>, Jochen S. Utikal<sup>g,h</sup>,  
Daniela Göppner<sup>i</sup>, Jessica C. Hassel<sup>j</sup>, Friedegund Meier<sup>k</sup>,  
Julia K. Tietze<sup>l</sup>, Ioannis Thomas<sup>b</sup>, Carsten Weishaupt<sup>m</sup>,  
Martin Leverkus<sup>n,†</sup>, Renate Wahl<sup>n</sup>, Ursula Dietrich<sup>k</sup>, Claus Garbe<sup>b</sup>,  
Michael C. Kirchberger<sup>a</sup>, Thomas Eigentler<sup>b</sup>, Carola Berking<sup>l</sup>,  
Anja Gesierich<sup>o</sup>, Angela M. Krackhardt<sup>p</sup>, Dirk Schadendorf<sup>e</sup>,  
Gerold Schuler<sup>a</sup>, Reinhard Dummer<sup>d</sup>, Lucie M. Heinzerling<sup>a,\*</sup>

<sup>a</sup> Department of Dermatology, University Hospital Erlangen, Friedrich-Alexander-University Erlangen-Nürnberg (FAU), Germany

<sup>b</sup> Department of Dermatology, University Hospital Tübingen, Germany

<sup>c</sup> Department of Dermatology, University Hospital Mainz, Germany

<sup>d</sup> Department of Dermatology, University Hospital Zurich, Switzerland

<sup>e</sup> Department of Dermatology, University Hospital, University Duisburg-Essen, Germany

<sup>f</sup> Department of Dermatology and Allergy, Skin Cancer Center Hannover, Hannover Medical School, Germany

<sup>g</sup> Skin Cancer Unit, German Cancer Research Center (DKFZ), Heidelberg, Germany

<sup>h</sup> Department of Dermatology, Venereology and Allergology, University Medical Center Mannheim, Ruprecht-Karl University of Heidelberg, Mannheim, Germany

<sup>i</sup> Department of Dermatology, University Hospital Magdeburg, Germany

<sup>j</sup> Department of Dermatology, University Hospital Heidelberg, Germany

<sup>k</sup> Department of Dermatology, University Hospital Dresden, Germany

<sup>l</sup> Department of Dermatology and Allergology, Ludwig-Maximilian-University (LMU) Munich, Germany

<sup>m</sup> Department of Dermatology, University Hospital Münster, Münster, Germany

<sup>n</sup> Department of Dermatology, University Hospital RWTH Aachen, Germany

<sup>o</sup> Department of Dermatology, University Hospital Würzburg, Germany

<sup>p</sup> III. Medical Department, Technische Universität München (TUM), Munich, Germany

Received 22 February 2016; accepted 25 February 2016

Available online 13 April 2016

\* Corresponding author: Department of Dermatology, University Hospital Erlangen, Friedrich-Alexander-University Erlangen-Nürnberg (FAU), 91054 Erlangen, Germany. Tel.: +49 9131 85 39037; fax: +49 9131 85 36175.

E-mail address: [Lucie.Heinzerling@uk-erlangen.de](mailto:Lucie.Heinzerling@uk-erlangen.de) (L.M. Heinzerling).

† We like to commemorate Martin Leverkus who was a wonderful colleague, a talented researcher and a good friend.

<http://dx.doi.org/10.1016/j.ejca.2016.02.025>

0959-8049/© 2016 Elsevier Ltd. All rights reserved.

**KEYWORDS**

Anti-PD-1;  
Side-effect;  
Toxicity;  
Pembrolizumab;  
Nivolumab;  
Checkpoint inhibitors;  
Tolerability;  
Immune-related;  
Adverse event

**Abstract Background:** Anti-programmed cell death receptor-1 (PD-1) antibodies represent an effective treatment option for metastatic melanoma as well as for other cancer entities. They act via blockade of the PD-1 receptor, an inhibitor of the T-cell effector mechanisms that limit immune responses against tumours. As reported for ipilimumab, the anti-PD-1 antibodies pembrolizumab and nivolumab can induce immune-related adverse events (irAEs). These side-effects affect skin, gastrointestinal tract, liver, endocrine system and other organ systems. Since life-threatening and fatal irAEs have been reported, adequate diagnosis and management are essential.

**Methods and findings:** In total, 496 patients with metastatic melanoma from 15 skin cancer centers were treated with pembrolizumab or nivolumab; 242 side-effects were described in 138 patients. In 116 of the 138 patients, side-effects affected the skin, gastrointestinal tract, liver, endocrine, and renal system. Rare side-effects included diabetes mellitus, lichen planus, and pancreas insufficiency due to pancreatitis.

**Conclusion:** Anti-PD1 antibodies can induce a plethora of irAEs. The knowledge of them will allow prompt diagnosis and improve the management resulting in decreased morbidity.

© 2016 Elsevier Ltd. All rights reserved.

## 1. Introduction

Nivolumab and pembrolizumab have been shown to enhance pre-existing immune responses including anti-tumour response by directly blocking programmed cell death receptor-1 (PD-1) which is a checkpoint of the effector stage of the immune system [1,2]. While the response rate of ipilimumab-treated patients is around 10–15% [3,4], response rates of pembrolizumab- and nivolumab-treated patients are 33% [5] and 32% [6], respectively.

Grade 3–4 adverse events (AEs) are observed in 22–24% of ipilimumab-treated patients [7,8], in 5–10% of nivolumab- and pembrolizumab-treated patients [5,6] and in 54–55% of ipilimumab plus nivolumab-treated patients [8,9]. A permanent discontinuation of therapy due to side-effects has been reported in 5% of patients treated with anti-PD-1 antibodies [10]. All checkpoint inhibitors can potentially induce immune-related AEs (irAEs) in any organ system. In contrast to ipilimumab, treatment with anti-PD-1 antibodies is continuous with some studies finishing application after 2 years. Thus, irAEs can occur late after initiation of therapy but possibly also after cessation of therapy. To date, cases of rare life-threatening or even fatal side-effects have been reported after anti-PD-1 antibody therapy like severe skin reactions [11], diabetes mellitus type 1 [12], and rhabdomyolysis [13].

Both nivolumab and pembrolizumab are approved for treatment of metastatic melanoma, nivolumab also for squamous non-small-cell lung cancer (NSCLC) after prior chemotherapy. Since they are also effective in various other tumour entities, they are expected to be employed widely. Therefore, physicians should be aware of potential side-effects. To facilitate prompt diagnosis

and adequate management, cutaneous, gastrointestinal, hepatic, endocrine, and renal side-effects are summarised. Rare and therapeutically challenging side-effects from 15 cancer centers in Germany and Switzerland are described in detail.

## 2. Methods

### 2.1. Ethics statement

This retrospective study was approved by the local institutional review board of the Friedrich-Alexander-University Erlangen-Nuremberg (approval number 17\_16Bc). In addition, all clinical protocols were reviewed and approved by the local institutional review boards of each participating center and were performed according to Good Clinical Practice and the Helsinki Declaration.

### 2.2. Study centers and treatment settings

Fifteen participating study centers in Germany and Switzerland screened patient files for pembrolizumab- and nivolumab-associated irAEs and reported them. AEs were graded according to the National Cancer Institute Common Toxicity Criteria (CTC, version 4.0). If not otherwise stated, pembrolizumab was administered intravenously over 30 min at a dose of 2 mg/kg body weight every 3 weeks and nivolumab over 60 min at a dose of 3 mg/kg body weight every 2 weeks. Based upon the authors' discretion, additional information was requested for the 15 most compelling and instructive cases of cutaneous, gastrointestinal, hepatic, endocrine, and renal side-effects.

### 3. Results

A total of 496 melanoma patients were treated with nivolumab or pembrolizumab at 15 skin cancer centers; 242 irAEs were reported in 138 patients. In 116 of the 138 patients, side-effects affected skin (43 patients), endocrine system (30 patients), gastrointestinal tract (21 patients), liver (11 patients), pancreas (9 patients), and the renal system (2 patients).

#### 3.1. Skin

Skin reactions are the most common side-effects under treatment with anti-PD-1 or anti-cytotoxic T-lymphocyte-associated protein 4 (CTLA-4) antibodies and play an important role for patients. Under treatment with ipilimumab, up to 50% of the patients suffer from pruritus and rash with very few serious adverse skin reactions (grade 3–5) [4,14,15]. Patients had skin reactions like rash and pruritus in 28–37% and vitiligo in 9–11% under nivolumab and pembrolizumab [5,16]. Furthermore, rare cutaneous side-effects like exacerbating psoriasis vulgaris [17–20], exfoliative dermatitis [20], and erythema multiforme [20,21] have been documented. Therapy with anti-PD-1 antibodies may also increase radiosensitivity and can thus in combination with radiotherapy induce acute skin reaction [11] similarly reported for B-Raf proto-oncogene, serine/threonine kinase (BRAF) inhibitors [22,23]. Also a case of lichen planus pemphigoides under treatment with pembrolizumab [24] and two cases of an induced bullous pemphigoid [25,26] were reported.

In our analysis, 43 patients (8.7%) presented with dermatological side-effects (Table 1). These included common skin events like pruritus, rash and eczema in 19 patients (3.8%), vitiligo in 13 patients (2.6%), alopecia in 7 patients (1.4%), and lichenoid and cytotoxic skin reactions in 4 patients (0.8%). Psoriasis vulgaris and lichen planus mucosae were reported in two patient each. Sweet's syndrome, lichen planus, and lichen sclerosus et atrophicus were documented in one patient each. Only three cutaneous AEs—lichenoid skin reaction, lichen ruber mucosae, and Sweet's syndrome—were graded as severe, i.e. grade 3. All other events were documented as grade 1–2 and could be managed with topical corticosteroids, systemic antihistaminic therapy, or did not require treatment. Only one patient with pruritus received systemic corticosteroid therapy. All grade 3 AEs led to pause of treatment with anti-PD-1 and resolved or improved even after continuation of anti-PD-1. The patient with lichenoid skin reaction received systemic prednisolone (1 mg/kg body weight orally [p.o.]).

##### 3.1.1. Patient 1—Vitiligo of the skin

A 55-year-old male patient with metastatic melanoma stage IV was treated with pembrolizumab. After 44

weeks of treatment, the patient developed a distinctive vitiligo with accentuation of his face and chest (Fig. 1A).

##### 3.1.2. Patient 2—Vitiligo of the hair

After systemic therapy with vemurafenib and ipilimumab, a 53-year-old woman with stage IV metastatic melanoma received pembrolizumab (10 mg/kg body weight intravenous [i.v.]) every 3 weeks. Eighteen weeks after the first cycle with pembrolizumab, the patient developed depigmentation of her eyelashes, eyebrows (Fig. 1B), and her axillary and pubic hair which still persists.

##### 3.1.3. Patient 3—Lichen planus mucosae

An 87-year-old male patient, pretreated with radiation therapy, carboplatin/paclitaxel and ipilimumab, was started on treatment with pembrolizumab. In addition to pneumonitis, vitiligo, and autoimmune hepatitis, the patient developed white pruritic and reticular plaques in his buccal cavity and on his tongue (Fig. 2A) approximately 1 year after initiation of anti-PD-1 treatment. Furthermore, he had a painful erosion on his glans penis (Fig. 2A). Histopathological analysis confirmed the diagnosis of lichen ruber planus mucosae. Direct and indirect immunofluorescence, antinuclear antibody (ANA) titer, and anti-desmoglein-3 and anti-desmoglein-1 antibodies were negative. Topical therapy with triamcinolone acetonide (adhesive ointment) for the buccal mucosa and with methylprednisolone for the balanitis was initiated. In addition, systemic analgesic therapy and local antiseptic therapy were administered. Four weeks later, almost all buccal and genital skin changes had resolved. Pembrolizumab was paused for 3 weeks and the lichen planus mucosae did not recidivate upon continuation of anti-PD1 therapy.

##### 3.1.4. Patient 4—Lichen planus

A 46-year-old patient started treatment with pembrolizumab for metastatic melanoma. After eight cycles, he developed painful and itchy hyperkeratotic papules and nodules at his hands, feet, forearms, and trunk (Fig. 2B). Histopathological analysis revealed lichen planus with hypergranulosis, orthohyperkeratosis, and dense lichenoid infiltrate in the upper corium and some apoptotic keratinocytes (civatte bodies; Fig. 2B). Local treatment with corticosteroids and urea- and salicylic acid-containing ointments as well as systemic therapy with levocetirizine 5 mg per day were started. After a few weeks, the skin lesions improved markedly. Computed tomography (CT) scans revealed regression of metastases. Treatment with pembrolizumab is currently ongoing. Local treatment with corticosteroids and urea- and salicylic acid-containing ointments as well as systemic therapy with levocetirizine 5 mg per day is continued.

Table 1  
Cutaneous side-effects of anti-PD1 therapy.

Type of side-effect	Grade CTCAE	Anti-PD-1 antibody	Occurrence in week(s) after initiation of anti-PD-1	Treatment of side-effect	Outcome of side-effect	Clinical tumour response to anti-PD-1	Gender (female/ male)	Age	Pre-treatments
Vitiligo	1	n	11	No treatment	Not resolved	PR	f	53	No prior treatment
Vitiligo (hypopigmentation around naevi)	1	n	35	No treatment	Not resolved	PR	m	66	No prior treatment
Vitiligo	1	p	54	No treatment	Not resolved	SD	f	61	Dacarbazine; ipilimumab; carboplatin/paclitaxel;
Vitiligo	1	p	39	No treatment	Not resolved	PR	m	46	fotemustine Binimetinib; dacarbazine; anti-endosialin-antibody; ipilimumab
Vitiligo	2	p	20	No treatment	Not resolved	PR	f	71	Polychemotherapy with hydroxyurea; dacarbazine; carmustine
Vitiligo of hair	1	p	18	No treatment	Not resolved	PR	f	53	Vemurafenib; ipilimumab
Lichen planus mucosae	2	n	43	Topical corticosteroids; topical pimecrolimus; stomatitis mouthwash solution	Improved	PD	f	65	No prior treatment
Alopecia	1	p	27	No treatment	Improved	SD	m	52	Interferon-alpha; Mage-A3 vaccine; paclitaxel; ipilimumab (including 2 reinductions); polychemotherapy; intranodal vaccine; radiotherapy
Pruritus	1	p	4	No treatment	Improved	PD	m	68	Temozolomid; cisplatin; sorafenib; irinotecan; ipilimumab
Pruritus	1	p	24	Topical triclosan; topical corticosteroids; topical polidocanol	Not resolved	PR	f	65	Dacarbazine; ipilimumab
Pruritus/eczema	1	n	24	Topical methylprednisolone	Not resolved	PR	f	34	No prior treatment
Pruritus/xerosis cutis	1	n	2	No treatment	Not resolved	PD	m	70	Electrochemotherapy; ipilimumab
Pruritus/eczema	2	p	4	Topical corticosteroids; systemic corticosteroids 0.5 mg/kg/d p.o.; pause of pembrolizumab	Improved	PR	m	54	Dacarbazine; ipilimumab; radiotherapy; carboplatin/ paclitaxel
Pruritus	1	p	1	Topical methylprednisolone	Resolved	SD	m	79	Radiotherapy; ipilimumab
Pruritus	2	p	4	Fexofenadin 180 mg/d; topical corticosteroids	Resolved	SD	m	66	Interferon-alpha; radiotherapy
Pruritus	2	p	9	Clemastine fumarate p.o., hydroxyzine dihydrochloride 25 mg/d p.o.	Not resolved	PD	m	53	Interferon-alpha; ipilimumab; dacarbazine; carboplatin/paclitaxel; radiotherapy

(continued on next page)

Table 1 (continued)

Type of side-effect	Grade CTCAE	Anti-PD-1 antibody	Occurrence in week(s) after initiation of anti-PD-1	Treatment of side-effect	Outcome of side-effect	Clinical tumour response to anti-PD-1	Gender (female/ male)	Age	Pre-treatments
Erysipelas-like skin inflammation around responding cutaneous metastases	2	n	6	No treatment	Ongoing	SD	m	60	Interferon-alpha; interferon pegylated; ipilimumab
Eczema	1	n	4	Topical corticosteroids	Resolved	PD	m	78	Interferon-alpha
Pruritus	2	p	1	Topical corticosteroids; topical polidocanol	Resolved	PD	m	59	Radiotherapy; ipilimumab
Rash	2	p	1	Topical corticosteroids; topical polidocanol	Resolved	PD	m	59	Radiotherapy; ipilimumab
Hair growth (body)	1	p	26	No treatment	Not resolved	PR	m	55	Interferon-alpha; radiotherapy; dacarbazine; ipilimumab; vemurafenib
Hyperkeratosis (body)	1	p	26	No treatment	Not resolved	PR	m	55	Interferon-alpha; radiotherapy; dacarbazine; ipilimumab; vemurafenib
Vitiligo	2	p	44	No treatment	Not resolved	PR	m	55	Interferon-alpha; radiotherapy; dacarbazine; ipilimumab; vemurafenib
Pruritus/eczema	2	p	1	Topical hydrocortisone; topical mometasone furoate; topical urea	Improved	SD	f	81	Dacarbazine; SIRT; ipilimumab; radiotherapy
Rash face	2	p	1	Topical hydrocortisone; topical mometasone furoate; topical ketoconazole	Resolved	SD	f	81	Dacarbazine; SIRT; ipilimumab; radiotherapy
Vitiligo	1	p	1	No treatment	Not resolved	PR	m	69	Radiochemotherapy; carboplatin/paclitaxel; ipilimumab
Pruritus	1	p	1	Indifferential topical therapy; antihistaminic p.o.	Resolved	PR	m	69	Radiochemotherapy; carboplatin/paclitaxel; ipilimumab
Pruritus	1	p	12	No treatment	Not resolved	PR	m	64	Radiotherapy; dacarbazine; carboplatin/ paclitaxel; ipilimumab
Pruritus	1	p	27	Indifferential topical therapy	Improved	CR	m	54	Interferon-alpha; DC vaccine; ipilimumab
Hyperkeratosis (fingers)	2	p	3	No treatment	Not resolved	PD	m	49	Interferon-alpha; radiotherapy; ipilimumab; dabrafenib; dabrafenib/ trametinib
Pruritus	2	p	1	Topical corticosteroids; topical polidocanol	Resolved	SD	m	69	Interferon-alpha; dacarbazine; ipilimumab
Lichenoid skin reaction	3	p	1	Prednisolone 1 mg/kg/d; pause of pembrolizumab	Resolved	PD	m	79	Ipilimumab
Vitiligo	1	p	51	No treatment	Not resolved	PR	m	74	Ipilimumab
Lichenoid skin reaction	1	p	54	No treatment	Resolved	PR	m	74	Ipilimumab

Vitiligo	1	p	50	No treatment	Not resolved	PR	m	49	MEK inhibitor/ panBRAF-inhibitor; ipilimumab; cisplatin/ vindesine
Cytotoxic skin reaction	1	p	3	Topical corticosteroids; indifferent topical therapy	Resolved	SD	m	83	Ipilimumab
Rash	1	p	7	Topical corticosteroids	Resolved	PR	m	35	Ipilimumab
Rash	1	p	6	Topical corticosteroids	Resolved	PR	m	68	Ipilimumab
Vitiligo	1	p	50	No treatment	Not resolved	PR	m	68	Ipilimumab
Vitiligo	1	p	25	No treatment	Not resolved	PR	m	80	Dacarbazine; ipilimumab
Lichenoid skin reaction	1	p	38	Topical corticosteroids	Not resolved	PR	m	80	Dacarbazine; ipilimumab
Vitiligo	1	p	3	No treatment	Not resolved	PD	f	57	Ipilimumab
Cold hands	1	n	1	No treatment	Resolved	PR	m	76	Ipilimumab (including reinduction); radiotherapy
Lichen sclerosus et atrophicus	1	n	68	No treatment	Resolved	PR	m	76	Ipilimumab (including reinduction); radiotherapy
Alopecia	1	n	75	No treatment	Resolved	PR	f	62	Interferon-alpha
Febrile neutropenia with rash (sweet's syndrome)	3	n	10	Pause of nivolumab	Resolved	CR	f	70	No prior treatment
Alopecia	1	n	22	No treatment	Not resolved	CR	f	70	No prior treatment
Penis oedema	1	n	7	No treatment	Resolved	PR	m	71	No prior treatment
Psoriasis vulgaris	1	n	53	Topical calcipotriol and betamethasone	Not resolved	PR	m	71	No prior treatment
Alopecia	1	n	7	No treatment	Not resolved	SD	f	59	Ipilimumab
Atopic dermatitis (worsening)	1	n	2	Topical moisturising ointment	Not resolved	PD	m	45	Interferon-alpha; ipilimumab; radiotherapy
Alopecia (loss of eyelashes)	1	p	11	No treatment	Resolved	PR	f	29	Interferon-alpha; dacarbazine; ipilimumab; paclitaxel
Alopecia (loss of eyelashes)	1	p	35	No treatment	Resolved	PR	f	29	Interferon-alpha; dacarbazine; ipilimumab; paclitaxel
Decreased growth of hair (body)	1	p	19	No treatment	Not resolved	PR	f	29	Interferon-alpha; dacarbazine; ipilimumab; paclitaxel
Lichen planus	2	p	21	Topical corticosteroids and urea- and acetylsalicylic acid-containing ointments; systemic levocetirizine 5 mg/d	Improved	PR	m	45	Interferon-alpha; dacarbazine/darleukin; ipilimumab; carboplatin/ paclitaxel
Psoriasis vulgaris (worsening)	2	p	2	Topical therapy	Improved	SD	m	69	Interferon-alpha; dacarbazine; ipilimumab
Lichen planus mucosae	3	p	49	Topical triamcinolone and methylprednisolone; topical antiseptic therapy; systemic analgesic therapy; pause of pembrolizumab	Improved	PR	m	69	Radiochemotherapy; carboplatin/paclitaxel; ipilimumab
Exanthema (maculated)	2	p	1	Prednisolone 60 mg/d p.o. over 3 d; cetirizine p.o.	Improved	n/a	f	30	Radiotherapy; interferon-alpha; DC vaccine

Abbreviations: p, pembrolizumab; n, nivolumab; CTCAE, Common Terminology Criteria for Adverse Events; SD, stable disease, PR, partial response; CR, complete response, PD, progressive disease; n/a, not applicable; SIRT, selective internal radiation therapy; DC, dendritic cell; p.o., oral.



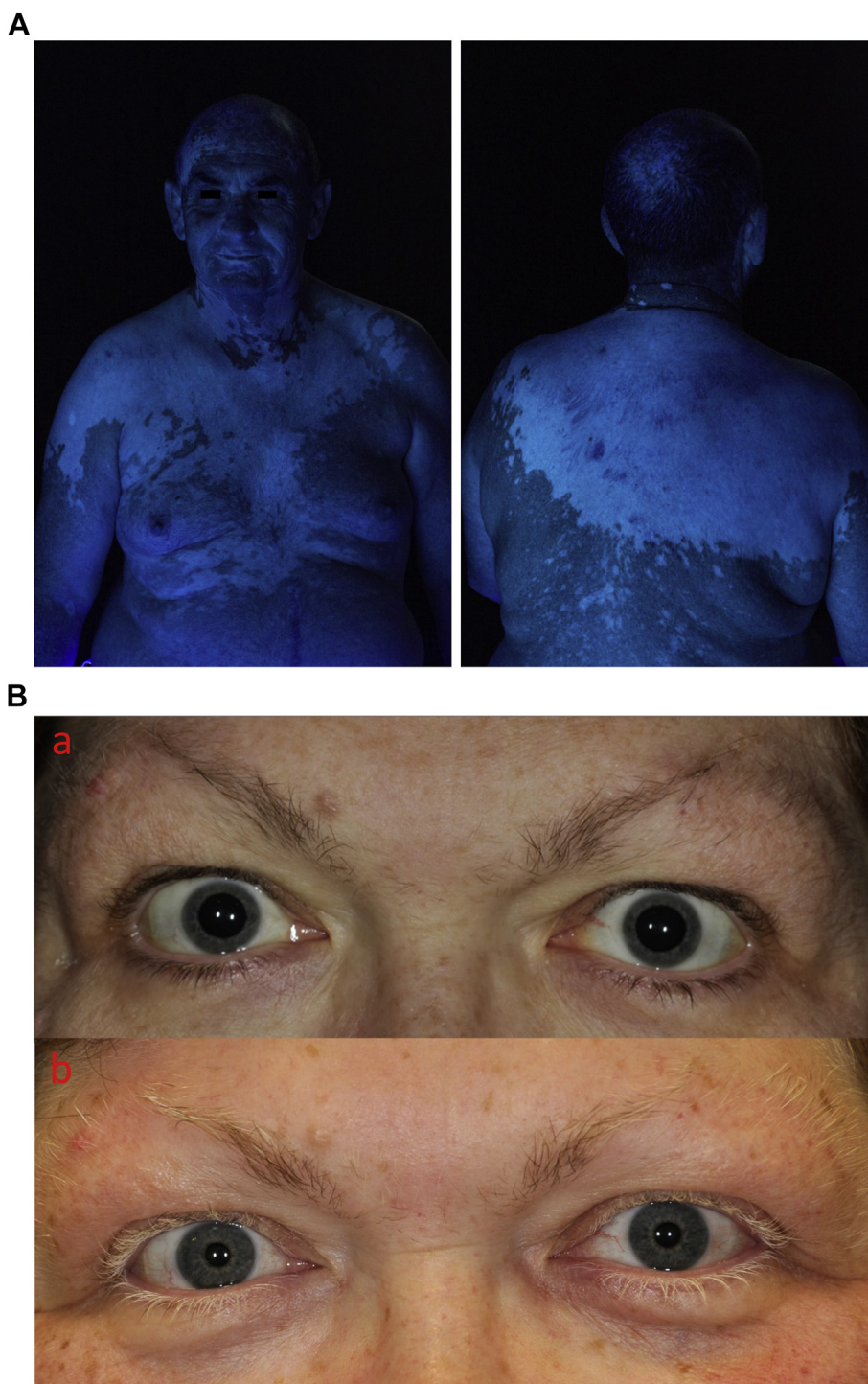


Fig. 1. (A) Vitiligo of the skin: depigmentation of the upper body and head with a bizarre and irregular border under black light in a melanoma patient after 44 weeks under treatment with pembrolizumab. (B) Vitiligo of the hair: eyebrows and eyelashes of a 53-year-old female patient before (a) and 18 weeks after treatment with pembrolizumab (b).

### 3.1.5. Patients 5, 6 and 7—alopecia

**Patient 5:** A 62-year-old female patient complained about hair loss starting after 35 infusions of nivolumab as first-line treatment of metastatic melanoma. Apart from that, she had tolerated the therapy well. The degree of hair loss varied but a wig or other therapeutic

intervention was not needed. Under ongoing anti-PD-1 treatment, the AE resolved after 2 months.

**Patient 6:** A 70-year-old female patient complained about hair loss starting after eight infusions of nivolumab as first-line treatment of metastatic melanoma. The patient was terrified from the sudden onset of hair loss

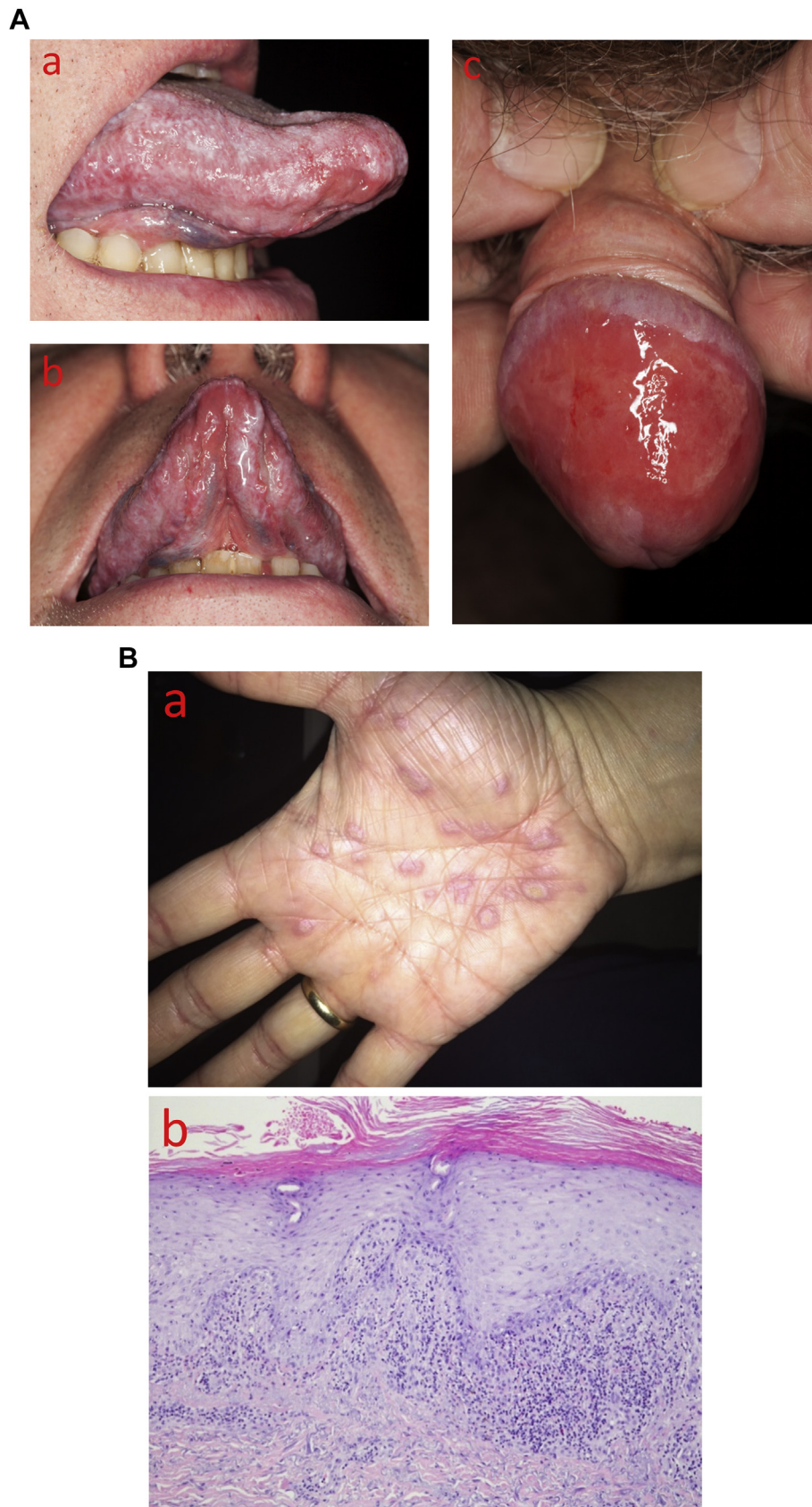


Fig. 2. (A) Lichen planus mucosae: 87-year-old male patient with pruritic, reticular white lines on the tongue (a, b) and an erosion of the glans penis (c) 49 weeks after initiation of pembrolizumab. (B) Lichen planus: on both palms of a 46-year-old pembrolizumab-treated male patient circumscribed, disseminated, and reddened papules with a shiny surface (a). Biopsy of the back of the hand with hyperkeratosis, wedge-shaped acanthosis, subepidermal dense lichenoid infiltrate of small lymphocytes that obscures the dermal–epidermal interface (b).



and chose to wear a wig. The degree of hair loss varied over time and was judged not to be severe. After two-and-a-half months, the AE resolved without interruption of anti-PD-1 treatment.

**Patient 7:** A 59-year-old female patient received three infusions of nivolumab because of progressive metastatic melanoma after therapy with ipilimumab. She complained about increasing hair loss. The density of her hair was reduced in all areas but mainly in a circle at the parietal region. Signs of hair loss alternate with hair growth at the parietal region and are ongoing, but not severe.

### 3.1.6. Patient 8—*Psoriasis vulgaris*

After 53 weeks of treatment with nivolumab, a 71-year-old male patient developed erythema and scales on his face. He had no history of psoriasis or atopic dermatitis. Topical treatment with hydrocortisone gel, followed by metronidazole under the suspected diagnosis of corticosteroid-induced dermatitis or rosacea was started. Contact allergy was ruled out by epicutaneous testing. Histology showed a subacute eczema with acanthokeratosis, parahyperkeratosis and spongiosis. The lesions slowly spread and psoriasis was diagnosed presenting with patches of thick, red, and scaly skin on the whole body (including elbows, knees, groins and genital). Under topical therapy including vitamin D analogues in combination with corticosteroids, the skin lesions improved and after cessation of nivolumab, psoriasis slowly resolved.

### 3.2. Gastrointestinal tract

Gastrointestinal irAEs are common under a treatment with checkpoint inhibitors. Ipilimumab-induced diarrhoea and colitis have been described in 32.8% and abdominal pain in 15.3% with grade 3–4 AEs in approximately 5% [3,27]. Patients under treatment with anti-PD-1 antibodies showed gastrointestinal AEs like diarrhoea in 6.0–16.0% [10,28,29] with grade 3–4 AEs in up to 2.2% [9,10,29,30]. Compared to ipilimumab, the incidence and severity of anti-PD-1 antibody-induced gastrointestinal AEs are much lower [27]. Nevertheless, intestinal perforations under anti-PD-1 treatment have been reported. An elevated calprotectin concentration in the feces before initiation of anti-CTLA-4 antibody therapy or a rapid increasing concentration under treatment seems to correlate with more severe autoimmune-related colitis [31]. As reported for ipilimumab to avoid mucosal biopsies, a non-invasive method for diagnosing checkpoint inhibitor-induced colitis *in vivo* is confocal laser endomicroscopy [32].

In this study, 21 patients (4.2%) were reported with gastrointestinal AEs (Table 2) including diarrhoea (10 patients), colitis (2 patients), abdominal pain (4 patients), coprostasis (3 patients), xerostomia (3 patients), and oesophagitis (1 patient). The majority of gastrointestinal

events were mild and only four grade 3 AEs (diarrhoea) were reported. In persisting grade 2 and grade 3 AEs, checkpoint inhibitor treatment was interrupted and prednisolone (1.0–2.0 mg/kg body weight p.o. or i.v.) administered. Two of the patients suffering from grade 3 diarrhoea received treatment with infliximab (5 mg/kg body weight i.v.). All gastrointestinal events resolved or were ongoing but improving.

### 3.3. Liver

Hepatitis is another side-effect that can be induced by checkpoint inhibitors. It may be even fatal [3]. Commonly, hepatitis presents with an asymptomatic increase of aspartate transaminase, alanine transaminase and total bilirubin. Sometimes fatigue and fever are associated and radiologic signs of a checkpoint inhibitor-induced hepatitis include hepatomegaly, periportal lymphadenopathy and periportal oedema [33]. Elevated transaminases are reported in <10% in ipilimumab-treated patients [3,27,34] and in 3.7–10.0% anti-PD-1 antibody-treated patients [16,35]. Also a cytomegalovirus (CMV)-induced hepatitis after treatment with ipilimumab has been reported [36]. However, 20% of patients treated for advanced hepatocellular carcinoma showed an increase in transaminases due to treatment with nivolumab [37].

In this study, 11 patients (2.2%) developed hepatitis under treatment with pembrolizumab or nivolumab (Table 3). All events were grade 3–4 and were subsequently treated with prednisolone or methylprednisolone 2 mg/kg body weight p.o. or i.v. while checkpoint inhibitors were interrupted or stopped. Three patients also required treatment with mycophenolate mofetil (500 mg or 1.0 g twice a day [BID] p.o.). Two events improved but were ongoing, all other hepatic AEs resolved.

#### 3.3.1. Patient 9—Hepatitis

After progressive disease under subsequent therapy with vemurafenib and ipilimumab, a 53-year-old female patient with stage IV metastatic melanoma received pembrolizumab (10 mg/kg body weight i.v.) every 3 weeks. Three weeks after the first infusion, the patient presented in a reduced general condition with massive increase of liver transaminases and painful red eyes with photophobia diagnosed as grade 3 iritis. Anti-PD-1 treatment was stopped. Liver biopsy revealed periportal and lobular hepatitis infiltrated with eosinophils and some other inflammatory cells (Fig. 3A). Since systemic steroids (prednisolone 2 mg/kg body weight i.v.) induced only a slight improvement in liver transaminases, mycophenolate mofetil 1 g p.o. BID was added. Hepatic transaminases responded within 24 h and normalised 1 month from the start of mycophenolate without relapse. Iritis was treated with mydriatic agents and dexamethasone eye drops and resolved completely after 4 weeks.

Table 2  
Gastrointestinal side-effects of anti-PD1 therapy.

Type of side-effect	Grade CTCAE	Anti-PD-1 antibody	Occurrence in week(s) after initiation of anti-PD-1	Treatment of side-effect	Outcome of side-effect	Clinical tumour response to anti-PD-1	Gender (female/male)	Age	Pre-treatments
Diarrhoea	3	p	24	Prednisolone 2 mg/kg/d i.v.; pause of pembrolizumab	Resolved	PR	f	71	Polychemotherapy with hydroxyurea; dacarbazine; carmustine
Lymphocytic colitis with diarrhoea	3	p	49	Prednisolone 2 mg/kg/d i.v.; infliximab 5 mg/kg i.v.; pause of pembrolizumab	Resolved	SD	f	68	Isolated limb perfusion; dacarbazine; fotemustine; vemurafenib; ipilimumab; temozolomide; electrochemotherapy with bleomycin
Diarrhoea	2	p	2	Prednisolone 2 mg/kg/d i.v.	Resolved	PD	f	50	No prior treatment
Diarrhoea	3	p	23	Systemic saccharomyces boulardii; loperamide p.o.; palliative analgesic therapy	Resolved	PD	f	40	Interferon-alpha; vemurafenib; ipilimumab; radiotherapy
Diarrhoea	1	p	4	No treatment	Not resolved	PD	f	44	Interferon-alpha; dabrafenib; ipilimumab; vemurafenib; radiotherapy
Colitis	2	p	5	Stop of pembrolizumab; loperamide; initial prednisolone 140 mg/d, tapering	Resolved	SD	m	66	Interferon-alpha; radiotherapy
Xerostomia	1	p	21	Saliva spray	Resolved	PR	m	78	No prior treatment
Pain abdomen	1	p	6	No treatment	Resolved	PD	m	67	Interferon-alpha; dacarbazine; vaccine; radiotherapy; carboplatin/paclitaxel
Diarrhoea	1	p	1, 4	No treatment	Resolved	PD	m	45	Interferon-alpha; dacarbazine; carboplatin/paclitaxel; carboplatin; vaccine; radiotherapy; ipilimumab (including reinduction)
Pain abdomen	1	p	1, 4	No treatment	Resolved	PD	m	45	Interferon-alpha; dacarbazine; carboplatin/paclitaxel; carboplatin; vaccine; radiotherapy; ipilimumab (including reinduction)
Pain abdomen	1	p	15	Fluid replacement p.o.; warm wet pack	Resolved	PD	m	52	Radiotherapy; carboplatin/paclitaxel; HFTT; ipilimumab
Coprostasis	2	p	1	Dexamethasone p.o.	Resolved	PR	m	55	Interferon-alpha; radiotherapy; dacarbazine; ipilimumab; vemurafenib
Pain abdomen	1	p	1, 28	No treatment	Resolved	PR	m	64	Radiotherapy; dacarbazine; carboplatin/paclitaxel; ipilimumab
Oesophagitis	2	p	24	Pantoprazole p.o.	Resolved	PR	m	64	Radiotherapy; dacarbazine; carboplatin/paclitaxel; ipilimumab
Diarrhoea	3	p	15	First line: prednisolone 80 mg/d p.o.; second line: pause of pembrolizumab; infliximab 5 mg/kg i.v.	Improved	PR	m	68	Radiotherapy; dacarbazine; dabrafenib; dabrafenib/trametinib; carboplatin/paclitaxel; ipilimumab
Diarrhoea	2	n	7	Pause of nivolumab; loperamide p.o.	Resolved	PD	f	68	No prior treatment
Diarrhoea	2	n	8	Loperamide p.o.; probiotic bacteria p.o.	Not resolved	PD	f	36	Radiotherapy; ipilimumab; dacarbazine
Xerostomia	1	n	10	No treatment	Not resolved	PR	m	76	Ipilimumab (including reinduction); radiotherapy
Coprostasis	1	n	6	Polyethylene glycol p.o. as needed	Resolved	PR	m	71	No prior treatment

(continued on next page)

Table 2 (continued)

Type of side-effect	Grade CTCAE	Anti-PD-1 antibody	Occurrence in week(s) after initiation of anti-PD-1	Treatment of side-effect	Outcome of side-effect	Clinical tumour response to anti-PD-1	Gender (female/male)	Age	Pre-treatments
Diarrhoea	1	n	19	Pause of nivolumab	Resolved	SD	m	45	Interferon-alpha; ipilimumab; radiotherapy
Xerostomia/dry nose	1	n	6	Topical therapy	Not resolved	PR	f	49	Vemurafenib; dabrafenib; ipilimumab; radiotherapy
Coprostasis	1	n	5	Polyethylene glycol p.o.	Not resolved	PD	m	52	Ipilimumab; radiotherapy
Diarrhoea	1	p	3	Metronidazole; butylscopolaminium-bromide; saccharomyces cerevisiae; fluid replacement	Resolved	PR	f	73	Interferon-alpha; dacarbazine; ipilimumab; radiotherapy

Abbreviations: p, pembrolizumab; n, nivolumab; CTCAE, Common Terminology Criteria for Adverse Events; SD, stable disease, PR, partial response; PD, progressive disease; HFTT, high-frequency chemotherapy; p.o., Oral; i.v., intravenous.

### 3.4. Pancreas

Under treatment with anti-CTLA-4 antibodies and anti-PD-1 antibodies grade 3–4 CTCAE elevated levels of serum amylase and lipase were reported in <1–2% [6,20,21,38]. Most of these events were asymptomatic and required no immunosuppressive therapy [39]. Interestingly, some authors do not recommend routine assessment of pancreatic enzymes [14]. In this analysis, nine patients developed pancreatitis (1.8%) of grade 2–4 under treatment with nivolumab or pembrolizumab (Table 4). All patients were treated with systemic corticosteroids ((methyl)prednisolone 1.0–2.0 mg/kg body weight) and treatment was interrupted in four patients. Two patients (grade 4 AEs) additionally required treatment with mycophenolate mofetil. Almost all events resolved with one patient still suffering from pancreas insufficiency.

#### 3.4.1. Patient 10—Pancreatitis with pancreas insufficiency

A 65-year-old male patient suffered from stage IV melanoma with hepatic and splenic metastases. After progressive disease under systemic treatment with a mitogen-activated protein kinase (MEK) inhibitor and ipilimumab, anti-PD-1 therapy with pembrolizumab was started. Eleven weeks after initiation, the patient suffered from lack of appetite and pain of his feet. One week later, the patient complained about increasing anorexia, nausea after eating, and an aversion against meat and weight loss. Laboratory findings showed an increased lipase (760 U/l, normal 13–60 U/l) and amylase (378 U/l, <110 U/l). Abdominal CT revealed a reduced lobulation, tissue swelling, and reduced tissue contrast enhancement of the pancreatic body and tail consistent with a pancreatitis (Fig. 3B). Systemic therapy with prednisolone (100 mg/d i.v.) was initiated, and after 3 d of treatment pancreas enzymes decreased (lipase 760 to 62 U/l and amylase 378 to 99 U/l). Corticosteroid therapy was changed to oral treatment (prednisolone 1 mg/kg body weight) and tapered. The following 5 months an increase of pancreatic enzymes was seen intermittently and led to consecutive enhanced corticosteroid therapy. The first staging 4 months after start of anti-PD-1 therapy showed a mixed tumour response with regressive hepatic but progressive splenic metastases. Eight months after start and nearly 2 months after end of treatment with anti-PD-1, the patient complained about irregular stools with diarrhoea, decolouration of faeces, and absent weight gain despite good appetite. Now pancreatic enzymes were decreased (lipase 7 U/l, normal 13–60 U/l and amylase 46 U/l, normal <110 U/l) and scotscopy showed a decreased level of elastase (<15 µg/g feces, normal >200 µg/g feces). A pancreas insufficiency was diagnosed and enzymes replaced orally with pancreatic enzyme capsules.

Commonly, asymptomatic increases of pancreatic enzymes have been described so that routine assessment was not recommended [14]. However, this case leading

Table 3  
Hepatic side-effects of anti-PD1 therapy.

Type of side-effect	Grade CTCAE	Anti-PD-1 antibody	Occurrence in week(s) after initiation of anti-PD-1	Treatment of side-effect	Outcome of side-effect	Clinical tumour response to anti-PD-1	Gender (female/male)	Age	Pre-treatments
Hepatitis	3	p	3	Prednisolone 2 mg/kg/d i.v.; mycophenolate mofetil 2× 1 g/d; stop of pembrolizumab	Resolved	PR	f	53	Vemurafenib; ipilimumab
Hepatitis	3	p	1	Stop of pembrolizumab; initial prednisolone 2 mg/kg/d, then: prednisolone 1 g/d i.v.	Resolved	PD	f	46	Interferon-alpha; ipilimumab; electrochemotherapy with bleomycin; interleukin-2 intralesional
Hepatitis	3	p	4	Pause of pembrolizumab; prednisolone 1 mg/kg/d p.o.	Resolved	PR	m	69	Radiochemotherapy; carboplatin/paclitaxel; ipilimumab
Hepatitis	3	n	4	Prednisolone 1 mg/kg/d	Resolved	PR	m	53	No prior treatment
Hepatitis	3	p	3	Prednisolone 2 mg/kg/d	Resolved	PD	f	48	Ipilimumab
Hepatitis	4	p	3	Stop of pembrolizumab; prednisolone 100 mg/d i.v. 3 d; prednisolone 500 mg/d i.v. 3 d; prednisolone 250 mg/d i.v. 7 d; mycophenolate mofetil 500 mg 2×/d and prednisolone 50 mg/d p.o. 14 d	Resolved	PD	f	35	Ipilimumab
Hepatitis	4	n	2	Methylprednisolone 2 mg/kg/d; stop of nivolumab	Improved	PR	m	76	Ipilimumab; radiotherapy
Hepatitis	3	p	4	Pause of pembrolizumab; prednisolone initial 50 mg/d	Resolved	PD	f	75	Dacarbazine; ipilimumab; radiotherapy
Hepatitis	3	p	2	Pause of pembrolizumab; methylprednisolone 1 mg/kg/d i.v., then p.o. and tapering to prednisolone 5 mg/d	Resolved	PR	f	56	Ipilimumab
Hepatitis	3	p	18	Stop of pembrolizumab; methylprednisolone 2 mg/kg/d; mycophenolate mofetil 500 mg 2×/d; prednisolone p.o., tapering	Resolved	CR	m	72	Interferon-alpha; ipilimumab
Hepatitis	3	p	1	Prednisolone 2 mg/kg/d p.o.; stop of pembrolizumab	Improved	n/a	m	55	Interferon-alpha; radiotherapy; ipilimumab

Abbreviations: p, pembrolizumab; n, nivolumab; CTCAE, Common Terminology Criteria for Adverse Events; PR, partial response; CR, complete response, PD, progressive disease; n/a, not applicable; p.o., oral; i.v., intravenous.

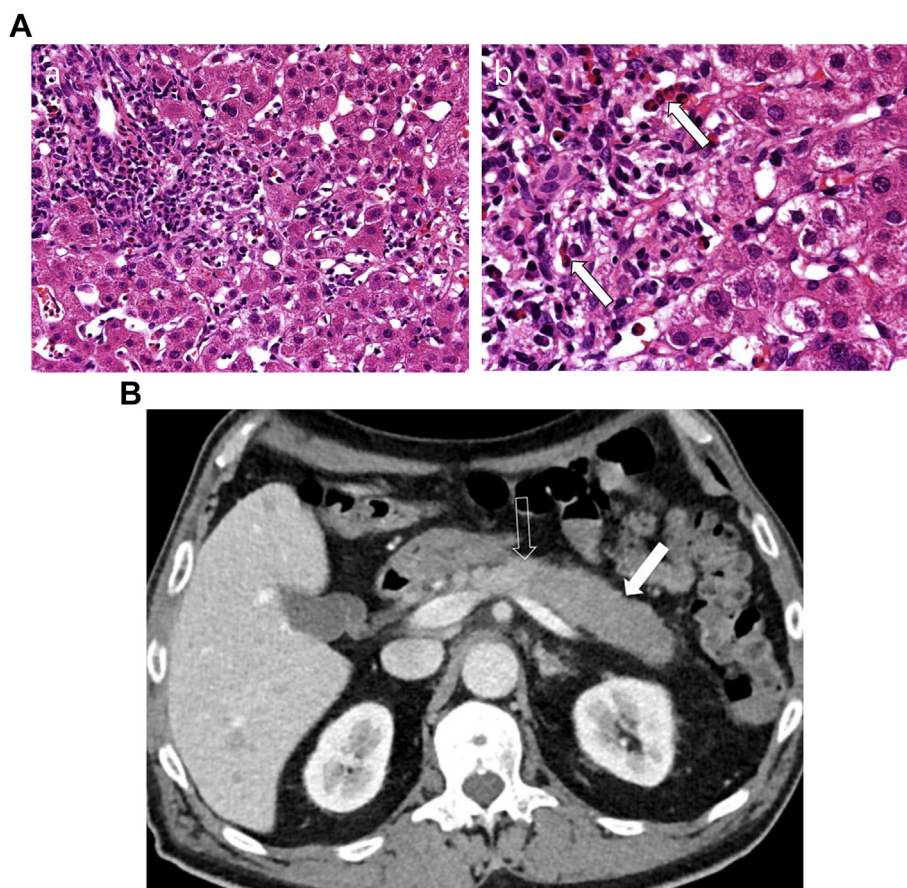


Fig. 3. (A) Hepatitis: histologic presentation of the liver of a 53-year-old female patient showing a (peri-)portal and lobular hepatitis with eosinophilic infiltrates ( $\rightarrow$ ), in haematoxylin and eosin stain (HE) stain, 200 times (a) and 400 times (b) magnified, 3 weeks after the first pembrolizumab treatment. (B) Pancreatitis with pancreas insufficiency: transversal contrast-enhanced computed tomography scan readily reveals reduced lobulation, tissue swelling, and reduced tissue contrast enhancement of the pancreatic body and tail consistent with pancreatitis (white solid arrow) compared to normal pancreatic tissue appearance in the pancreatic body (open arrow). Please note multifocal hypodense liver metastases of this 65-year-old male patient 11 weeks after initiation of anti-PD-1 treatment with pembrolizumab.

to pancreas insufficiency indicates that assessing these values is important.

### 3.5. Endocrine system

IrAEs of the endocrine system are well known from ipilimumab. Common endocrinopathies under anti-CTLA-4 include hyperthyroidism, hypothyroidism (1.5%), hypophysitis (1.8%), and adrenal insufficiency (1.5%) [3,40]. Under treatment with anti-PD-1 antibodies, incidence of hypothyroidism of any grade is approximately 8% [39] and of hyperthyroidism approximately 1–5% [5,20,21].

Endocrine disorders may be difficult to diagnose since symptoms of hypophysitis for instance can be unspecific with fatigue, headache, dizziness, vision changes, sweating, and constipation. Diagnosis is based on hormone work-up and magnetic resonance imaging (MRI) scans which might reveal enlargement of the pituitary gland [41]. Laboratory work-up includes electrolytes,

thyroidea-stimulating hormone (TSH), free triiodothyronine (fT3), free thyroxine (fT4), cortisol, luteinising hormone, follicle-stimulating hormone, circulating cortisol, testosterone, and insulin-like growth factor-1. Upon diagnosis, prompt treatment with hormones, electrolytes, and/or fluid replacement as required are indicated.

In our analysis, 30 patients (6.0%) developed endocrine disorders (Table 5). Approximately 25% of the events were grade 3–4. Hypothyroidism was reported in 9 patients (1.8%) and hyperthyroidism including thyroiditis in 11 patients (2.2%). Four patients (0.8%) developed hypophysitis and two patients adrenal insufficiency. Furthermore, Hashimoto's disease was documented in two cases. Four patients (0.8%) developed diabetes mellitus under treatment with nivolumab or pembrolizumab. In all cases, insulin replacement, in one case an insulin perfusor, had to be initiated and maintained. Initial symptoms included increased thirst,



Table 4  
Pancreatic side-effects of anti-PD1 therapy.

Type of side-effect	Grade CTCAE	Anti-PD-1 antibody	Occurrence in week(s) after initiation of anti-PD-1	Treatment of side-effect	Outcome of side-effect	Clinical tumour response to anti-PD-1	Gender (female/ male)	Age	Pre-treatments
Edematous pancreatitis	2	p	20	Prednisolone 1 mg/kg p.o.	Resolved	CR	f	63	Dacarbazine; ipilimumab
Pancreatitis	2	p	20	Systemic corticosteroids	Improved	PR	m	78	Dacarbazine; ipilimumab; radiotherapy; carboplatin/paclitaxel
Pancreatitis	2	p	6	Systemic corticosteroids	Improved	PR	m	71	Dabrafenib; ipilimumab; radiotherapy
Pancreatitis	3	n	12	Systemic corticosteroids	Resolved	PR	m	76	Dacarbazine; ipilimumab
Pancreatitis	4	p	9	Stop of pembrolizumab; prednisolone 1 mg/kg; mycophenolate mofetil	Resolved	PD	m	47	Radiotherapy; ipilimumab
Pancreatitis	4	p	9	Stop of pembrolizumab; prednisolone 1 mg/kg; mycophenolate mofetil	Resolved	PR	m	77	Radiotherapy; ipilimumab
Pancreatitis	3	n	2	Methylprednisolone 2 mg/kg; stop of nivolumab	Resolved	PR	m	76	Ipilimumab; radiotherapy
Pancreatitis	3	p	16	Pause of pembrolizumab; prednisolone; fluid replacement	Resolved	PR	m	55	Interferon-alpha; dacarbazine; ipilimumab; paclitaxel
Pancreatitis with pancreas insufficiency	3	p	11	Prednisolone 100 mg/d i.v. 3 d, then prednisolone 1 mg/kg p.o., tapering	Pancreatitis: resolved; pancreas insufficiency: not resolved	MR	m	65	MEK inhibitor; ipilimumab

Abbreviations: p, pembrolizumab; n, nivolumab; CTCAE, Common Terminology Criteria for Adverse Events; PR, partial response; PD, progressive disease; CR, complete response; MEK, mitogen-activated protein kinase.

vomiting, and ketoacidosis with increased glucose levels similar to the case of a fulminant diabetes type 1 reported in the literature [12].

### 3.5.1. Patient 11—Hypophysitis

A 52-year-old male patient, treated with ipilimumab (1 mg/kg body weight i.v.) combined with pembrolizumab (2 mg/kg body weight i.v.) as first-line treatment complained about general weakness, fatigue, lack of appetite, pressure in his ears, and shivering 17 weeks after initiation of treatment. A few days later, he also suffered from less saliva. Endocrine blood tests showed decreased fasting-free cortisol (0 ng/ml, normal 67–226 ng/ml) and adrenocorticotropic hormone (<5.0 pg/ml, normal 5–50 pg/ml), decreased testosterone (3.28 ng/ml, normal 3.5–9 ng/ml), increased interstitial cell-stimulating hormone (8.88 U/l, normal 0.7–6 U/l), increased TSH (6.78 µE/ml, normal 0.4–4.0 µE/ml), increased thyroglobulin (13.10 ng/ml, normal <1.0 ng/ml), and increased prolactin (281.1 mIU/l, normal 55.93–278.18 mIU/l). A systemic corticosteroid treatment with hydrocortisone 10 mg (2–1.5–0) and thyroxine orally was initiated. MRI of the hypophysitis showed a precise extension of the posterior pituitary and contrast medium uptake of the pituitary stalk. After initiation of systemic corticosteroids replacement, the general state of the patient improved.

### 3.5.2. Patients 12, 13 and 14—Diabetes mellitus type 3

Patient 12: A 70-year-old female patient with no history of diabetes and normal body mass index (20.6) sought medical advice after four treatments of first-line therapy with nivolumab because of increased thirst and circulatory problems. She was admitted because of high blood sugar levels and insulin therapy was started. A new-onset insulin-dependent diabetes type 3 accompanied by a hyperthyreosis was diagnosed. The glutamic acid decarboxylase (GAD) and the islet antigen-2 (IA2) antibodies were negative, and c-peptide was low (<16 pmol/l, normal 140–830 pmol/l). The cause of the sudden onset of the diabetes was considered to be an autoimmune reaction triggered by nivolumab. An MRI scan revealed regression of melanoma and the therapy with nivolumab was continued to maintain the good tumour response that is still present as well as the insulin-dependent diabetes.

Patient 13: A 78-year-old female patient with known diabetes mellitus type 2, which was well controlled with lifestyle changes (diet, physical activity) and without the need for medication, was started on treatment with nivolumab because of progressive metastatic melanoma after therapy with ipilimumab. Metformin was recommended right before initiation of nivolumab. After two infusions of nivolumab, the patient presented with vomiting, diarrhoea, and ketoacidosis. She was promptly admitted and symptomatic treatment as well as an insulin

perfusor was started. In the course of the hospitalisation, the patient developed ketoacidosis again and was transferred to the intensive care unit. The GAD antibodies were positive, the c-peptide low, and the IA2 antibodies were negative. Sudden pancreatic beta cell failure due to an autoimmune reaction induced by the anti-PD-1 antibodies was diagnosed. The newly diagnosed type 3 diabetes mellitus is currently under control and requires insulin therapy.

**Patient 14:** A 58-year-old female patient with no history of diabetes mellitus had progressive metastatic melanoma after therapy with ipilimumab. At presentation for second cycle of pembrolizumab, she complained about increased thirst and a persistent urge to urinate that had started the day before. A new- and sudden-onset insulin-dependent diabetes mellitus type 3 was diagnosed with low c-peptide, positive GAD II antibodies and IA2 antibodies at the upper limit of normal. An insulin therapy was initiated and after stabilisation of the blood glucose levels the second infusion of pembrolizumab was administered. The patient continues with the eighth infusion of pembrolizumab with stable findings of metastatic disease.

### 3.6. Renal system

IrAEs affecting the renal system are rare under treatment with anti-CTLA-4 [42] with anecdotic cases of nephritis [42], acute granulomatous interstitial nephritis [43], renal failure with atypical pneumonia, vision loss, and hearing loss [44] and lupus nephritis [45]. Similarly, anti-PD-1 antibodies only rarely induce AEs affecting the renal system with renal failure/nephritis reported in up to 1% of pembrolizumab- or nivolumab-treated patients [5,16,46]. Usually, pause of treatment and administration of corticosteroids (0.5–2.0 mg/kg body weight p.o. or i.v.) usually result in marked improvement [42,47]. In this study, three cases of renal failure/nephritis were documented in two patients (0.4%; Table 6). Both patients responded well to corticosteroid treatment (1.0 mg/kg body weight p.o. and i.v.) and i.v. substitution of electrolytes. Because of ongoing elevated creatinine, in one case a supportive adjuvant application of i.v. fluid before treatment was necessary.

#### 3.6.1. Patient 15—(Interstitial) Nephritis

A 52-year-old male patient with progressive melanoma after therapy with ipilimumab received the third infusion of nivolumab. In the laboratory tests, a grade 2 increase in creatinine was detected. The findings in the urine test were compatible with an interstitial nephritis and prednisolone 100 mg i.v. was started. In addition, the patient received i.v. fluids and the potentially nephrotoxic drugs, i.e. enalapril, indapamide, glimepiride, and dapagliflozin were stopped. Treatment with nivolumab was withheld. After a quick improvement to

grade 1 after 3 d, the therapy with corticosteroids was stopped. After 12 d, the AE was resolved and nivolumab therapy was restarted. On the day of admission, creatinine slightly increased again and, therefore, 500 ml of 0.9% sodium chloride were administered right after the administration of nivolumab. Additional fluids were given before all following infusions. Creatinine increased again and has varied in the course of the treatment but not higher than grade 1. After discontinuation of nivolumab treatment because of progressive disease and the start of dexamethasone therapy because of progression of brain metastases with surrounding oedema, creatinine completely normalised.

## 4. Discussion

In this study, 496 patient records of 15 skin cancer centers were screened for anti-PD-1 AEs and 242 interesting, rare or unexpected, side-effects induced by nivolumab or pembrolizumab were documented in 138 patients (27.8%). Cutaneous, gastrointestinal, hepatic, endocrine, and renal AEs occurred in 116 of the 138 patients and were summarised: Some events are reported for the first time like lichen planus and pancreas insufficiency after pancreatitis. Furthermore, details of rare side-effects like diabetes mellitus type 3 are reported in 4 patients.

Monitoring of patients for side-effects including laboratory findings before, during, and after anti-PD-1 therapy is essential. In accordance with the literature [39], cutaneous AEs under anti-PD-1 treatment are usually mild and well controlled by symptomatic therapy. Most commonly, rashes and vitiligo have been reported. Vitiligo did not require treatment and was associated with a high disease control rate of 92% (12 of 13 patients). This is in accordance with the literature with a disease control rate of 88% (15 in 17 patients) [48]. However, also severe grade 3 lichenoid skin lesions occurred. Interestingly, Goldinger et al. [49] observed in 22% of PD-1-treated patients inflammatory skin lesions ranging from mild maculopapular rashes, typically associated with scaling, and/or lichenoid lesions to very severe Stevens–Johnson syndrome-like skin lesions. Gene expression profiling pathogenically classified all investigated cases as toxic epidermal necrolysis-like reactions. Clinical and histological features of the lesions resembled the findings reported in mice with disrupted *PD-1* gene [50]. Overall, most reported AEs in this study were mild with grade 1–2. In this study 24% of AEs were severe (grade 3–4) and three AEs were fatal due to pneumonia and ventricular arrhythmia.

In summary, anti-PD-1 antibodies can affect any organ system and, thus, all symptoms have to be considered as potentially anti-PD-1 associated. Patients have to be accurately informed and instructed to report any symptom. Just as importantly medical staff has to

Table 5  
Endocrine side-effects of anti-PD1 therapy.

Type of side-effect	Grade CTCAE	Anti-PD-1 antibody	Occurrence in week(s) after initiation of anti-PD-1	Treatment of side-effect	Outcome of side-effect	Clinical tumour response to anti-PD-1	Gender (female/male)	Age	Pre-treatments
Diabetes mellitus type 3	3	n	6	First line: insulin perfusor; second line: protaphane/actrapid pen s.c.; pause of nivolumab	Not resolved	PD	m	40	Dacarbazine; polychemotherapy; ipilimumab
Hashimoto's thyroiditis, hypothyroidism	2	n	5	L-thyroxine 75 µg 1×/d	Not resolved	PR	f	53	No prior treatment
Hyperthyroidism	2	n	11	Prednisolone 40 mg p.o. 1×/d, tapering 4 weeks; pause of nivolumab	Hyperthyroidism: resolved; destructive thyroopathy: not resolved	PR	m	66	No prior treatment
Hyperthyroidism	1	p	3	No treatment	Resolved	SD	f	61	Dacarbazine; ipilimumab; carboplatin/paclitaxel; fotemustine
Hypothyroidism	2	p	9	L-thyroxine 50 µg 1×/d	Not resolved	SD	f	61	Dacarbazine; ipilimumab; carboplatin/paclitaxel; fotemustine
Hashimoto's thyroiditis, hypothyroidism	2	p	18	L-thyroxine 75 µg 1×/d	Not resolved	PR	m	46	MEK-inhibitor; dacarbazine; anti-endosialin-antibody; ipilimumab
Hypocortisolism	2	p	18	Hydrocortisone 15 mg/d p.o.	Not resolved	PR	m	46	Binimetinib; dacarbazine; anti-endosialin-antibody; ipilimumab
Pituitary gland: thyreotropic insufficiency	2	p	10	Dose escalation L-thyroxine 75 µg 1×/d	Not resolved	PR	f	71	Polychemotherapy with litalir; dacarbazine; carmustine
Hyperthyroidism	2	p	11	Stop of base medication L-thyroxine	Resolved	PD	f	54	Interferon-alpha; vemurafenib/cobimetinib; ipilimumab; radiotherapy
Hypothyroidism	1	p	7	No treatment	Not resolved	PD	f	44	Interferon-alpha; dabrafenib; ipilimumab; vemurafenib; radiotherapy
Hypophysitis with secondary adrenal insufficiency	4	p	20	Dexamethasone 4 mg 4×/d	Resolved	PD	m	79	No prior treatment
Hypothyroidism (worsening)	1	p	56	L-thyroxine	Not resolved	CR	f	63	Dacarbazine; ipilimumab
Thyroiditis	1	n	12	L-thyroxine	Not resolved	SD	f	54	Dabrafenib; ipilimumab
Thyroiditis	3	p	5	Initial: thiamazole (hyperthyroidism), following: L-thyroxine (hypothyroidism)	Not resolved	MR	m	83	Etoposide
Hypothyroidism	2	p	8	L-thyroxine 50 µg/d	Not resolved	SD	f	65	Ipilimumab; dacarbazine; SIRT; paclitaxel; radiotherapy
Hypothyroidism	2	p	13	L-thyroxine 50 µg/d	Not resolved	PR	m	78	Dacarbazine; ipilimumab; paclitaxel
Thyroiditis	2	p	3	Thyroid replacement	Not resolved	PD	m	72	Dabrafenib/trametinib; ipilimumab; carboplatin/paclitaxel
Hyperthyroidism	2	n	7	Carbimazole p.o.	Resolved	PD	f	64	Radiotherapy; SIRT
Hypothyroidism	2	p	6	No treatment	Not resolved	PR	f	48	Ipilimumab
Hyperthyroidism	1	p	15	No treatment	Resolved	PR	m	35	Ipilimumab
Hypothyroidism	1	p	6	No treatment	Not resolved	PR	m	80	Dacarbazine; ipilimumab
Hypothyroidism	2	p	10	L-thyroxine	Resolved	SD	f	63	Dacarbazine; ipilimumab

(continued on next page)

Table 5 (continued)

Type of side-effect	Grade CTCAE	Anti-PD-1 antibody	Occurrence in week(s) after initiation of anti-PD-1	Treatment of side-effect	Outcome of side-effect	Clinical tumour response to anti-PD-1	Gender (female/ male)	Age	Pre-treatments
Hyperthyroidism with thyroiditis	1	p	3	No treatment	Not resolved	PR	f	81	Dacarbazine; ipilimumab
Hyperthyroidism	2	p	4	Carbimazole	Not resolved	SD	m	60	Ipilimumab; dacarbazine
Diabetes mellitus type 3	3	n	6	Insulin therapy	Not resolved	CR	f	70	No prior treatment
Diabetes mellitus type 3	3	n	3	Insulin therapy	Not resolved	SD	f	78	Dacarbazine; ipilimumab; radiotherapy
Pituitary gland: insufficiency of the anterior lobe	3	n	5	Hydrocortisone p.o.	Not resolved	PD	m	44	Ipilimumab
Hypothyroidism	1	n	2	Methylprednisolone 2 mg/kg/d; stop of nivolumab	Not resolved	PR	m	76	Ipilimumab; radiotherapy
Hypophysitis, hypopituitarism	2	n	2	Hydrocortisone p.o.	Not resolved	PD	f	60	Ipilimumab; radiotherapy
Hyperthyroidism	1	n	5	Beta-blocker	Not resolved	PD	f	60	Ipilimumab; radiotherapy
Hypophysitis, hypopituitarism	3	n	5	Pause of nivolumab; prednisolone initial 50 mg/d	Not resolved	SD	f	72	Interleukin-2 intratumoural; imatinib; ipilimumab; radiotherapy; thermoablatio liver; electrochemotherapy with bleomycin
Diabetes mellitus type 3	3	p	3	Insulin therapy	Not resolved	SD	f	58	Ipilimumab; radiotherapy
Hypophysitis	2	i/p	17	Systemic hydrocortisone and thyroxine p.o.	Improved	SD	m	52	Radiotherapy

Abbreviations: p, pembrolizumab; n, nivolumab; i/p, ipilimumab/pembrolizumab; CTCAE, Common Terminology Criteria for Adverse Events; SD, stable disease; PR, partial response; PD, progressive disease; CR, complete response; MR, mixed response; SIRT, selective internal radiation therapy; MEK, mitogen-activated protein kinase; p.o., oral; s.c., subcutaneous.

Table 6  
Renal side-effects of anti-PD1 therapy.

Type of side-effect	Grade CTCAE	Anti-PD-1 antibody	Occurrence in week(s) after initiation of anti-PD-1	Treatment of side-effect	Outcome of side-effect	Clinical tumour response to anti-PD-1	Gender (female/male)	Age	Pre-treatments
Nephritis with renal failure	3	p	2	Prednisolone 1 mg/kg/d p.o.	Improved	n/a	m	73	Interferon-alpha; ipilimumab +/- nivolumab
Nephritis	2	n	5	Pause of nivolumab; prednisolone 100 mg/d 3 d; sodium chloride 500 ml i.v. with following infusions	Resolved	PD	m	52	Ipilimumab; radiotherapy
Nephritis	1	n	7	Sodium chloride 500 ml i.v. with following infusions	Resolved	PD	m	52	Ipilimumab; radiotherapy

Abbreviations: p, pembrolizumab; n, nivolumab; CTCAE, Common Terminology Criteria for Adverse Events; PD, progressive disease; n/a, not applicable; p.o., oral; i.v., intravenous.

be informed and remain aware of the side-effect profile of these immunotherapies. Quite often irAEs start quite subtle with minimal symptoms. If symptoms are auto-immune related, prompt treatment including high-dose corticosteroids can be necessary. Treatment with anti-PD-1 antibodies only has to be paused when AEs are severe and can often be resumed as documented in our study. If AEs are life threatening, anti-PD-1 treatment has to be discontinued.

#### Conflict of interest statement

Andrea Forschner is on the advisory board or/and has received honoraria from Merck Sharp & Dohme, Bristol-Meyers Squibb, Roche, and Novartis and travel support from MSD, Roche, and Novartis. Carmen Loquai is on the advisory board or/and has received honoraria or/and travel support from Roche, BMS, Merck, and Novartis. Simone Goldinger has received travel support from BMS, MSD, Roche, and Novartis and grants from University of Zurich. Lisa Zimmer is on the advisory board and/or has received honoraria from Roche, Bristol-Myers Squibb, MSD, GSK, Novartis, and Merck and travel support from MSD, BMS, and Novartis. Selma Ugurel has received grants and travel support from Medac, personal fees from Roche and MSD, and travel support from BMS. Ralf Gutzmer has received personal fees from BMS, MSD, Merck, Roche, Novartis, GlaxoSmithKline, Pfizer, Amgen, Almirall-Hermal, LEO, Galderma, Janssen, Boehringer Ingelheim, grants from Novartis, Pfizer, Johnson & Johnson, and non-financial support from BMS, Novartis, GSK, and Amgen. Jochen Utikal has received financial support for performing clinical trials with PD-1 inhibitors from MSD and BMS and is on the advisory board from Roche, Novartis, GSK, and MSD; Daniela Göppner has received personal fees from Roche, BMS, Amgen, and MSD and non-financial support from Roche, Novartis, and Amgen. Jessica Hassel has received scientific support

(investigator initiated trial) from BMS and is on the advisory board or/and has received honoraria from BMS, MSD, Roche, GSK, Novartis, and Amgen. Julia Tietze has received honoraria from Roche, MSD, BMS, and Novartis. Ioannis Thomas has received travel support from Roche. Carsten Weishaupt has received honoraria from BMS and MSD. Claus Garbe is on the advisory board or/and has received honoraria from Amgen, BMS, MSD, Novartis, Roche, and LEO and grants from BMS, Novartis and Roche. Thomas Eigentler is on the advisory board from BMS and has received travel support from MSD; Carola Berking is on the advisory board and/or has received honoraria from BMS, MSD, GSK, Novartis, Roche, Merck, Amgen, and AstraZeneca. Anja Gesierich has received travel support from MSD and BMS. Angela Krackhardt has received personal fees and grants from BMS. Dirk Schadendorf has received personal fees and patients' fees from Roche, Novartis, GSK, Merck, and BMS and personal fees from Amgen, Boehringer Ingelheim, and LEO. Reinhard Dummer is on the advisory board and has received honoraria from Roche, BMS, MSD, GSK, Novartis, and Amgen and research funding from Roche, BMS, GSK, MSD, and Novartis. Lucie Heinzerling has received honoraria from BMS and MSD, travel support from BMS, and financial support for performing clinical trials from MSD and BMS. All other authors have nothing to declare.

#### Funding

No additional funding was available for this study.

#### Acknowledgements

The authors would like to thank G. Metzler, Tübingen, and S. Schliep, Erlangen, for histopathologic diagnosis and reporting. The authors thank T. Bley,



Würzburg, for kindly providing a radiologic image. C. Bender, Heidelberg, has kindly supported patient documentation. The present work was performed in fulfillment of the requirements for obtaining the degree 'Dr. med'.

## References

- Okazaki T, Honjo T. PD-1 and PD-1 ligands: from discovery to clinical application. *Int Immunol* [Internet] 2007 Jul;19(7):813–24 [cited 2015 Feb 25]; Available from: <http://www.ncbi.nlm.nih.gov/pubmed/17606980>.
- Ribas A. Tumor immunotherapy directed at PD-1. *N Engl J Med* [Internet] 2012 Jun 28;366(26):2517–9 [cited 2015 Aug 21]; Available from: <http://www.ncbi.nlm.nih.gov/pubmed/22658126>.
- Hodi FS, O'Day SJ, McDermott DF, Weber RW, Sosman JA, Haanen JB, et al. Improved survival with ipilimumab in patients with metastatic melanoma. *N Engl J Med* [Internet] 2010 Aug 19;363(8):711–23 [cited 2014 Jul 9]; Available from: <http://www.pubmedcentral.nih.gov/articlerender.fcgi?artid=3549297&tool=pmcentrez&rendertype=abstract>.
- Robert C, Thomas L, Bondarenko I, O'Day S, Weber J, Garbe C, et al. Ipilimumab plus dacarbazine for previously untreated metastatic melanoma. *N Engl J Med* [Internet] 2011 Jun 30;364(26):2517–26 [cited 2015 Aug 28]; Available from: <http://www.ncbi.nlm.nih.gov/pubmed/21639810>.
- Robert C, Schachter J, Long GV, Arance A, Grob JJ, Mortier L, et al. Pembrolizumab versus ipilimumab in advanced melanoma. *N Engl J Med* [Internet] 2015 Apr 19;372(26):1504–15 [cited 2015 Apr 21]; Available from: <http://www.ncbi.nlm.nih.gov/pubmed/25891173>.
- Weber JS, D'Angelo SP, Minor D, Hodi FS, Gutzmer R, Neyns B, et al. Nivolumab versus chemotherapy in patients with advanced melanoma who progressed after anti-CTLA-4 treatment (Check-Mate 037): a randomised, controlled, open-label, phase 3 trial. *Lancet Oncol* [Internet] 2015 Apr;16(4):375–84 [cited 2015 Jun 3]; Available from: <http://www.ncbi.nlm.nih.gov/pubmed/25795410>.
- O'Day SJ, Maio M, Chiarion-Sileni V, Gajewski TF, Pehamberger H, Bondarenko IN, et al. Efficacy and safety of ipilimumab monotherapy in patients with pretreated advanced melanoma: a multicenter single-arm phase II study. *Ann Oncol* [Internet] 2010 Aug;21(8):1712–7 [cited 2015 Sep 14]; Available from: <http://www.ncbi.nlm.nih.gov/pubmed/20147741>.
- Postow MA, Chesney J, Pavlick AC, Robert C, Grossmann K, McDermott D, et al. Nivolumab and ipilimumab versus ipilimumab in untreated melanoma. *N Engl J Med* [Internet] 2015 May 21;372(21):2006–17 [cited 2015 Apr 22]; Available from: <http://www.ncbi.nlm.nih.gov/pubmed/25891304>.
- Larkin J, Chiarion-Sileni V, Gonzalez R, Grob JJ, Cowey CL, Lao CD, et al. Combined nivolumab and ipilimumab or monotherapy in untreated melanoma. *N Engl J Med* [Internet] 2015 Jul 2;373(1):23–34 [cited 2015 Jun 2]; Available from: <http://www.ncbi.nlm.nih.gov/pubmed/26027431>.
- Topalian SL, Hodi FS, Brahmer JR, Gettinger SN, Smith DC, McDermott DF, et al. Safety, activity, and immune correlates of anti-PD-1 antibody in cancer. *N Engl J Med* [Internet] 2012 Jun 28;366(26):2443–54 [cited 2014 Aug 12]; Available from: <http://www.pubmedcentral.nih.gov/articlerender.fcgi?artid=3544539&tool=pmcentrez&rendertype=abstract>.
- Sibaud V, David I, Lamant L, Resseguier S, Radut R, Attal J, et al. Acute skin reaction suggestive of pembrolizumab-induced radiosensitization. *Melanoma Res* [Internet] 2015 Dec;25(6):555–8 [cited 2016 Feb 15]; Available from: <http://www.ncbi.nlm.nih.gov/pubmed/26312439>.
- Gaudy C, Clévy C, Monestier S, Dubois N, Préau Y, Mallet S, et al. Anti-PD1 Pembrolizumab can induce exceptional fulminant type 1 diabetes. *Diabetes Care* [Internet] 2015 Nov 26;38(11):e182–3 [cited 2015 Sep 14]; Available from: <http://www.ncbi.nlm.nih.gov/pubmed/26310693>.
- Min L, Hodi FS. Anti-PD1 following ipilimumab for mucosal melanoma: durable tumor response associated with severe hypothyroidism and rhabdomyolysis. *Cancer Immunol Res* [Internet] 2014 Jan;2(1):15–8 [cited 2016 Jan 10]; Available from: <http://www.pubmedcentral.nih.gov/articlerender.fcgi?artid=4006358&tool=pmcentrez&rendertype=abstract>.
- Postow MA. Managing immune checkpoint-blocking antibody side effects. *Am Soc Clin Oncol Educ Book* [Internet] 2015 Jan;35:76–83 [cited 2015 Jun 2]; Available from: <http://www.ncbi.nlm.nih.gov/pubmed/25993145>.
- Weber JS, Yang JC, Atkins MB, Disis ML. Toxicities of immunotherapy for the practitioner. *J Clin Oncol* [Internet] 2015 Jun 20;33(18):2092–9 [cited 2015 Oct 9]; Available from: <http://jco.ascopubs.org/content/33/18/2092.abstract>.
- Topalian SL, Sznol M, McDermott DF, Kluger HM, Carvajal RD, Sharfman WH, et al. Survival, durable tumor remission, and long-term safety in patients with advanced melanoma receiving nivolumab. *J Clin Oncol* [Internet] 2014 Apr 1;32(10):1020–30 [cited 2015 Mar 16]; Available from: <http://www.ncbi.nlm.nih.gov/pubmed/24590637>.
- Kato Y, Otsuka A, Miyachi Y, Kabashima K. Exacerbation of psoriasis vulgaris during nivolumab for oral mucosal melanoma. *J Eur Acad Dermatol Venereol* [Internet] 2015 Sep 21 [cited 2015 Nov 16]; Available from: <http://www.ncbi.nlm.nih.gov/pubmed/26388113>.
- Matsumura N, Ohtsuka M, Kikuchi N, Yamamoto T. Exacerbation of psoriasis during nivolumab therapy for metastatic melanoma. *Acta Derm Venereol* [Internet] 2015 Aug 13 [cited 2015 Nov 16]; Available from: <http://www.ncbi.nlm.nih.gov/pubmed/26270860>.
- Sahuquillo-Torralba A, Ballester-Sánchez R, Pujol-Marco C, Botella-Estrada R. Pembrolizumab: a new drug that can induce exacerbations of psoriasis. *Actas Dermosifiliogr* [Internet] 2015 Nov 3 [cited 2015 Nov 16]; Available from: <http://www.ncbi.nlm.nih.gov/pubmed/26546027>.
- Opdivo: highlights of prescribing information, [http://packageinserts.bms.com/pi/pi\\_opdivo.pdf](http://packageinserts.bms.com/pi/pi_opdivo.pdf) [accessed 08.10.15].
- Keytruda: highlights of prescribing information, [http://www.merck.com/product/usa/pi\\_circulars/k/keytruda/keytruda\\_pi.pdf](http://www.merck.com/product/usa/pi_circulars/k/keytruda/keytruda_pi.pdf) [accessed 12.10.15].
- Hecht M, Zimmer L, Loquai C, Weishaupt C, Gutzmer R, Schuster B, et al. Radiosensitization by BRAF inhibitor therapy-mechanism and frequency of toxicity in melanoma patients. *Ann Oncol* [Internet] 2015 Jun;26(6):1238–44 [cited 2016 Jan 25]; Available from: <http://www.ncbi.nlm.nih.gov/pubmed/25762352>.
- Pulvirenti T, Hong A, Clements A, Forstner D, Suchowersky A, Guminski A, et al. Acute radiation skin toxicity associated with BRAF inhibitors. *J Clin Oncol* [Internet] 2016 Jan 20;34(3):e17–20 [cited 2016 Feb 15]; Available from: <http://www.ncbi.nlm.nih.gov/pubmed/24868021>.
- Schmidgen MI, Butsch F, Steinbrink K, Weidenthaler-Barth B, Schmücker P, Jetter A, et al. Lichen planus pemphigoides bei einem 62-jährigen Patienten mit metastasiertem malignen Melanom und kompletter Remission nach Therapie mit Pembrolizumab. *J Dtsch Dermatol Ges* [Internet] 2015;13 (Suppl. S2, pages 20–64):40–1. Available from: <http://doi.wiley.com/10.1111/ddg.12784>.
- Carlos G, Anforth R, Chou S, Clements A, Fernandez-Peñas P. A case of bullous pemphigoid in a patient with metastatic melanoma treated with pembrolizumab. *Melanoma Res* [Internet] 2015 Jun;25(3):265–8 [cited 2015 Sep 21]; Available from: <http://www.ncbi.nlm.nih.gov/pubmed/25831416>.
- Vigl K, Wehsegruber F, Pirkhammer D, Rappersberger K. Generalisierte Blasenbildung unter Pembrolizumab-Therapie. *J Dtsch Dermatol Ges* [Internet] 2015;13 (Suppl. S2, pages 20–64):44–5. Available from: <http://doi.wiley.com/10.1111/ddg.12784>.
- Wolchok JD, Neyns B, Linette G, Negrier S, Lutzky J, Thomas L, et al. Ipilimumab monotherapy in patients with pretreated

- advanced melanoma: a randomised, double-blind, multicentre, phase 2, dose-ranging study. *Lancet Oncol* [Internet] 2010 Feb; 11(2):155–64 [cited 2015 Sep 21]; Available from: <http://www.ncbi.nlm.nih.gov/pubmed/20004617>.
- 28 Garon EB, Rizvi NA, Hui R, Leighl N, Balmanoukian AS, Eder JP, et al. Pembrolizumab for the treatment of non-small-cell lung cancer. *N Engl J Med* [Internet] 2015 May 21;372(21): 2018–28 [cited 2015 Apr 24]; Available from: <http://www.ncbi.nlm.nih.gov/pubmed/25891174>.
  - 29 Robert C, Long GV, Brady B, Dutriaux C, Maio M, Mortier L, et al. Nivolumab in previously untreated melanoma without BRAF mutation. *N Engl J Med* [Internet] 2015 Jan 22;372(4): 1411–16004513004. [cited 2014 Nov 16]; Available from: <http://www.ncbi.nlm.nih.gov/pubmed/25399552>.
  - 30 Brahmer J, Reckamp KL, Baas P, Crinò L, Eberhardt WEE, Poddubskaya E, et al. Nivolumab versus docetaxel in advanced squamous-cell non-small-cell lung cancer. *N Engl J Med* [Internet] 2015 Jul 9;373(2):123–35 [cited 2015 Jun 2]; Available from: <http://www.ncbi.nlm.nih.gov/pubmed/26028407>.
  - 31 Koop A, Gutzmer R, Satzger I, Bachmann O. Autoimmunitiden unter der Behandlung mit Checkpoint-Inhibitor - Calprotektin als prädiktiver Marker intestinaler Nebenwirkungen. *J Dtsch Dermatol Ges* [Internet] 2015;13 (Suppl. S2, pages 1–20):3. Available from: <http://doi.wiley.com/10.1111/ddg.12783>.
  - 32 Hundorfean G, Atreya R, Agaimy A, Heinzerling L, Kämpgen E, Schuler G, et al. Fluorescein-guided confocal laser endomicroscopy for the detection of ipilimumab-induced colitis. *Endoscopy* [Internet] 2012 Jan;44(Suppl 2):E78–9 [cited 2016 Jan 29]; Available from: <http://www.ncbi.nlm.nih.gov/pubmed/22396291>.
  - 33 Kim KW, Ramaiya NH, Krajewski KM, Jagannathan JP, Tirumani SH, Srivastava A, et al. Ipilimumab associated hepatitis: imaging and clinicopathologic findings. *Invest New Drugs* [Internet] 2013 Aug;31(4):1071–7 [cited 2015 Oct 8]; Available from: <http://www.ncbi.nlm.nih.gov/pubmed/23408334>.
  - 34 Bernardo SG, Moskalenko M, Pan M, Shah S, Sidhu HK, Sicular S, et al. Elevated rates of transaminitis during ipilimumab therapy for metastatic melanoma. *Melanoma Res* [Internet] 2013 Feb;23(1):47–54 [cited 2015 Oct 6]; Available from: <http://www.ncbi.nlm.nih.gov/pubmed/23262440>.
  - 35 Hamid O, Robert C, Daud A, Hodi FS, Hwu W-J, Kefford R, et al. Safety and tumor responses with lambrolizumab (anti-PD-1) in melanoma. *N Engl J Med* [Internet] 2013 Jul 11;369(2):134–44 [cited 2015 Sep 14]; Available from: <http://www.pubmedcentral.nih.gov/articlerender.fcgi?artid=4126516&tool=pmcentrez&rendertype=abstract>.
  - 36 Uslu U, Agaimy A, Hundorfean G, Harrer T, Schuler G, Heinzerling L. Autoimmune colitis and subsequent CMV-induced hepatitis after treatment with ipilimumab. *J Immunother* [Internet] 2015 Jun;38(5):212–5 [cited 2016 Jan 29]; Available from: <http://www.ncbi.nlm.nih.gov/pubmed/25962110>.
  - 37 El-Khoueiry AB, Melero I, Crocenzi TS, Welling TH, Yau TC, Yeo W, et al. Phase I/II safety and antitumor activity of nivolumab in patients with advanced hepatocellular carcinoma (HCC): CA209–040. *J Clin Oncol* [Internet] 2015;33 [cited 2015 Oct 8]; Available from: <http://meetinglibrary.asco.org/print/1987796>.
  - 38 Yervoy: summary of product characteristics, [http://www.ema.europa.eu/docs/en\\_GB/document\\_library/EPAR\\_-\\_Product\\_Information/human/002213/WC500109299.pdf](http://www.ema.europa.eu/docs/en_GB/document_library/EPAR_-_Product_Information/human/002213/WC500109299.pdf) [accessed 15.10.15].
  - 39 Naidoo J, Page DB, Li BT, Connell LC, Schindler K, Lacouture ME, et al. Toxicities of the Anti-PD-1 and Anti-PD-L1 immune checkpoint antibodies. *Ann Oncol* [Internet] 2015 Dec; 26(12):2375–91 [cited 2015 Sep 16]; Available from: <http://www.ncbi.nlm.nih.gov/pubmed/26371282>.
  - 40 Corseello SM, Barnabei A, Marchetti P, De Vecchis L, Salvatori R, Torino F. Endocrine side effects induced by immune checkpoint inhibitors. *J Clin Endocrinol Metab* [Internet] 2013 Apr;98(4): 1361–75 [cited 2015 Jul 17]; Available from: <http://www.ncbi.nlm.nih.gov/pubmed/23471977>.
  - 41 Araujo PB, Coelho MCA, Arruda M, Gadelha MR, Neto LV. Ipilimumab-induced hypophysitis: review of the literature. *J Endocrinol Invest* [Internet] 2015 Nov;38(11):1159–66 [cited 2016 Jan 18]; Available from: <http://www.ncbi.nlm.nih.gov/pubmed/25957829>.
  - 42 Voskens CJ, Goldinger SM, Loquai C, Robert C, Kaehler KC, Berking C, et al. The price of tumor control: an analysis of rare side effects of anti-CTLA-4 therapy in metastatic melanoma from the ipilimumab network. *PLoS One* [Internet] 2013 Jan;8(1):e53745 [cited 2015 Sep 9]; Available from: <http://www.pubmedcentral.nih.gov/articlerender.fcgi?artid=3544906&tool=pmcentrez&rendertype=abstract>.
  - 43 Izzedine H, Gueutin V, Gharbi C, Mateus C, Robert C, Routier E, et al. Kidney injuries related to ipilimumab. *Invest New Drugs* [Internet] 2014 Aug;32(4):769–73 [cited 2015 Sep 22]; Available from: <http://www.ncbi.nlm.nih.gov/pubmed/24687600>.
  - 44 Voskens C, Cavallaro A, Erdmann M, Dippel O, Kaempgen E, Schuler G, et al. Anti-cytotoxic T-cell lymphocyte antigen-4-induced regression of spinal cord metastases in association with renal failure, atypical pneumonia, vision loss, and hearing loss. *J Clin Oncol* [Internet] 2012 Nov 20;30(33):e356–7 [cited 2016 Jan 29]; Available from: <http://www.ncbi.nlm.nih.gov/pubmed/23045571>.
  - 45 Fadel F, El Karoui K, Knebelmann B. Anti-CTLA4 antibody-induced lupus nephritis. *N Engl J Med* [Internet] 2009 Jul 9; 361(2):211–2 [cited 2015 Sep 22]; Available from: <http://www.ncbi.nlm.nih.gov/pubmed/19587352>.
  - 46 Khoja L, Butler MO, Kang SP, Ebbinghaus S, Joshua AM. Pembrolizumab. *J Immunother cancer* [Internet] 2015 Jan;3:36 [cited 2015 Sep 15]; Available from: <http://www.pubmedcentral.nih.gov/articlerender.fcgi?artid=4539882&tool=pmcentrez&rendertype=abstract>.
  - 47 Forde PM, Rock K, Wilson G, O’Byrne KJ. Ipilimumab-induced immune-related renal failure—a case report. *Anticancer Res* [Internet] 2012 Oct;32(10):4607–8 [cited 2015 Oct 12]; Available from: <http://www.ncbi.nlm.nih.gov/pubmed/23060594>.
  - 48 Hua C, Boussemart L, Mateus C, Routier E, Boutros C, Cazenave H, et al. Association of Vitiligo with tumor response in patients with metastatic melanoma treated with pembrolizumab. *JAMA Dermatol* [Internet] 2016 Jan 1;152(1):45–51 [cited 2015 Nov 16]; Available from: <http://www.ncbi.nlm.nih.gov/pubmed/26501224>.
  - 49 Goldinger SM, Stieger P, Meier B, Micaletto S, Contassot E, French LE, et al. Cytotoxic cutaneous adverse drug reactions during anti-PD-1 therapy. *Clin Cancer Res*. (in revision). *Clin Cancer Res* [Internet] 2016 Mar 8 [cited 2016 Mar 16]; Available from: <http://www.ncbi.nlm.nih.gov/pubmed/26957557>.
  - 50 Nishimura H, Nose M, Hiai H, Minato N, Honjo T. Development of lupus-like autoimmune diseases by disruption of the PD-1 gene encoding an ITIM motif-carrying immunoreceptor. *Immunity* [Internet] 1999 Aug;11(2):141–51 [cited 2016 Feb 22]; Available from: <http://www.ncbi.nlm.nih.gov/pubmed/10485649>.