

Longitudinal Trajectories of Brain Volume and Cortical Thickness in Treated and Untreated Primary Human Immunodeficiency Virus Infection

Ryan Sanford,¹ Beau M. Ances,² Dieter J. Meyerhoff,³ Richard W. Price,⁴ Dietmar Fuchs,⁵ Henrik Zetterberg,^{6,7,8,9} Serena Spudich,^{10,a} and D. Louis Collins^{1,a}

¹Department of Biological and Biomedical Engineering, Montreal Neurological Institute, Quebec, Canada; ²Department of Neurology, University of Washington, St Louis, Missouri; Departments of ³Radiology and Biomedical Imaging and ⁴Neurology, University of California, San Francisco School of Medicine; ⁵Division of Biological Chemistry, Innsbruck Medical University, Austria; ⁶Department of Psychiatry and Neurochemistry, Sahlgrenska Academy, University of Gothenburg, and ⁷Clinical Neurochemistry Laboratory, Sahlgrenska University Hospital, Mölndal, Sweden; ⁸Department of Molecular Neuroscience, Institute of Neurology, and ⁹UK Dementia Research Institute, University College London, United Kingdom; and ¹⁰Department of Neurology, Yale School of Medicine, New Haven, Connecticut

Background. Human immunodeficiency virus (HIV) penetrates the brain in early infection. We used neuroimaging to longitudinally examine the impact of HIV and combination antiretroviral therapy (cART) on the brain in treated and untreated HIV-infected participants, starting in primary HIV infection (PHI).

Methods. Sixty-five participants, enrolled during PHI, underwent longitudinal magnetic resonance imaging, 30 of whom commenced cART during follow-up. Cross-sectional data from 16 patients with chronic HIV infection (CHI) and 19 HIV-uninfected participants were included for comparison. Brain volume and cortical thickness were estimated using tensor-based morphometry and cortical modeling, respectively. Mixed-effects models longitudinally mapped structural brain changes before and after cART. The relationship between brain morphometry estimates and blood and cerebrospinal fluid (CSF) biomarkers were also tested. Region-of-interest analyses were performed to compare brain morphometry estimates between the groups.

Results. Prior to cART, longer duration of untreated infection in PHI correlated with volume loss in the thalamus, caudate, and cerebellum, and with cortical thinning in the frontal and temporal lobes and cingulate cortex. After cART, no further volume loss was observed. However, small increases of cortical thickness in the frontal and temporal lobe correlated with longer cART duration. No correlations were observed with blood or CSF measures. The PHI group did not have different brain morphometric measures compared to the HIV-uninfected group, but had larger volumes in the thalamus, caudate, putamen, and cortical gray matter compared with CHI participants.

Conclusions. Subcortical atrophy and cortical thinning occur during untreated infection but may be arrested by cART. These findings emphasize the importance of early cART.

Keywords. primary HIV infection; brain morphometry; combination antiretroviral therapy; magnetic resonance imaging; HIV-associated neurocognitive disorders.

Human immunodeficiency virus (HIV) penetrates the central nervous system (CNS) soon after initial infection [1]. Despite the use of combination antiretroviral therapy (cART), people living with HIV continue to experience cognitive impairment [1–3]. The etiology of this mild, but quality-of-life-limiting brain dysfunction is unclear.

Recently, longitudinal studies demonstrated that well-treated, aviremic chronic HIV-infected (CHI; defined as >1 year after

exposure) individuals had significant brain volume reductions compared to controls at all visits, but changes in brain volume over time were similar in both groups [3, 4]. Although these results argue against an active, destructive process to be the cause of the brain alterations, the timing of these changes remains uncertain.

It has been hypothesized that structural brain alterations may occur in primary HIV infection (PHI; defined as <1 year after exposure), possibly before cART initiation [3]. Several studies have demonstrated that prominent inflammation [5–7], immune activation [8–10] and blood–brain barrier (BBB) disruption [11] were evident during the first year of infection, and progressively worsened in the absence of cART [5, 9, 11]. All of these factors have been linked to neuronal injury during this period [12], and could contribute, in part, to brain volume reductions previously reported in PHI individuals [13–15]. However, the natural course of structural brain

Received 21 December 2017; editorial decision 18 April 2018; accepted 23 April 2018; published online April 24, 2018.

^aS. S. and D. L. C. contributed equally to this work as principal investigators.

Correspondence: R. Sanford, McConnell Brain Imaging Center WB-324, Montreal Neurological Institute, 3801 University St, Montreal, Quebec H3A 2B4, Canada (ryan.sanford@mail.mcgill.ca).

Clinical Infectious Diseases® 2018;67(11):1697–704

© The Author(s) 2018. Published by Oxford University Press for the Infectious Diseases Society of America. All rights reserved. For permissions, e-mail: journals.permissions@oup.com. DOI: 10.1093/cid/ciy362

changes that occurs in early infection and the impact cART has on these changes are not well characterized [13–16].

In this longitudinal study, a large sample of HIV-infected participants, enrolled during PHI, were followed longitudinally, several of whom commenced cART during follow-up. For comparison, smaller cross-sectional samples of CHI participants and HIV-uninfected controls were acquired. We aimed to (1) map the trajectory of structural brain changes in PHI participants before cART; (2) assess whether cART stabilizes or reverses structural alterations; (3) compare structural brain measures at enrollment in the PHI group with the CHI and HIV-uninfected groups; and (4) explore the relationship between brain changes and blood and cerebrospinal fluid (CSF) biomarkers. Regional brain volume and cortical thickness were characterized with tensor-based morphometry (TBM) and cortical modeling, respectively. These approaches are useful for examining regional brain morphometry because they do not require anatomical hypotheses and they have previously been shown to be effective in detecting brain changes in people living with HIV [2, 3, 17, 18]. It is advantageous to use these methods in tandem because they provide complimentary information; whereas TBM is best suited to detect spatially localized volume changes in subcortical regions [18], cortical modeling is well suited to extracting cortical morphometric measures (eg, thickness) [2].

METHODS

Participants

Sixty-five HIV-infected participants starting in PHI were followed longitudinally at the University of California, San Francisco (UCSF) from 14 December 2005 to 22 December 2011. PHI was defined as infection within 12 months prior to enrollment, confirmed by the Serological Testing Algorithm for Recent HIV Seroconversion [19]. HIV transmission date was estimated as 14 days before onset of seroconversion symptoms, or as the date halfway between the last negative and first HIV-positive test [12]. Sixty-one PHI participants were cART-naïve at enrollment, while 4 PHI participants were cART-treated before enrollment (median cART duration before enrollment, 23 days [interquartile range {IQR}, 14.1–27.9 days]). Treatment was commenced by 26 PHI participants during follow-up, independent of the study. Cross-sectional data from 16 CHI and 19 HIV-uninfected participants were also collected at UCSF. The CHI participants had a history of HIV diagnosis for at least 3 years and were either cART-naïve ($n = 9$) or had elected to interrupt therapy for at least 3 months before entering the study ($n = 7$; mean time off therapy, 11.7 months). HIV-uninfected controls were recruited from the San Francisco community, and matched to PHI participants for age, sex, and education. Exclusion criteria included confounding active neurologic illness, active substance use (except tobacco, marijuana, and

alcohol), and hepatitis B or C coinfection. The Institutional Review Board at UCSF approved the study. Written informed consent was obtained from all participants.

Specimen Sampling, Processing, and Laboratory Analysis

Participants underwent detailed medical and neurological examinations as well as collection of blood and CSF specimens at each visit. Details of the laboratory analysis have been previously described [20]. In brief, blood samples were analyzed for CD4⁺ and CD8⁺ T-lymphocyte counts using flow cytometry. CSF samples were analyzed for neurofilament light chain (NFL), at enrollment in PHI only, with the neurofilament light enzyme-linked immunosorbent assay kit (UmanDiagnostics, Umeå, Sweden) [12]. Paired blood and CSF samples were analyzed for white blood cell (WBC) count and albumin, while paired blood and cell-free CSF samples were analyzed for HIV RNA and neopterin concentrations [20]. These measures were considered biomarkers of viral burden (blood and CSF HIV RNA), immune status (CD4⁺ and CD8⁺ T-lymphocyte counts), inflammation (blood and CSF neopterin, and WBC counts), BBB permeability (CSF:albumin ratio), and neuronal injury (NFL).

Magnetic Resonance Imaging Acquisition

All participants underwent magnetic resonance imaging (MRI) using the same MedSpec 4T Siemens (Erlangen, Germany) TRIO console in San Francisco. The scanning protocol included a T1-weighted 3-dimensional magnetization-prepared rapid acquisition gradient echo sequence (repetition time/echo time/inversion time = 2300/3.0/950 ms; voxel = 1.0 mm³). PHI participants completed longitudinal MRI scans, whereas HIV-uninfected and CHI participants completed 1 scan. MRI and laboratory data were acquired at enrollment, 6 weeks, and every 6 months thereafter. While some MRI and laboratory data were not acquired on the same date, they were associated with the same study interval. MRIs were obtained a median of 12 days (IQR, 6–23.5 days) from each associated laboratory visit.

MRI Processing

All PHI T1-weighted data were processed using a longitudinal processing pipeline, as previously described [3, 21]. Preprocessing included de-noising, intensity inhomogeneity removal [22], and brain masking [23]. Images were linearly registered to the Montreal Neurological Institute ICBM152 template using a 9-parameter affine transform [24]. To ensure the registrations to the ICBM152 space were consistent across all visits, a subject-specific template was created using an unbiased template creation approach [25]. This process yielded nonlinear transformations that mapped each visit to the ICBM152 space in a consistent manner reducing the intrasubject variability in brain volume measures, increasing the statistical power to detect within-subject changes [21, 26]. Cross-sectional T1-weighted data for HIV-uninfected and CHI participants followed similar

processing procedures, except the scans were nonlinearly registered directly to the ICBM152 template [26]. All data were carefully inspected for unacceptable processing outcomes. All data passed visual quality control.

Tensor-based Morphometry

TBM provides a voxel-wise estimate of brain structure volume relative to the ICBM152 template. Structural volumes were calculated by taking the Jacobian determinant of the deformation field from the nonlinear transform [27].

Cortical Modeling

Cortical modeling provides a quantitative measure of cortical thickness. Cortical thickness estimates were extracted with fast accurate cortical extraction by deforming polygonal meshes to fit the gray-white matter and pial surface boundaries [28]. Thickness estimates were mapped to the ICBM152 average cortical template using an iterative feature-based registration algorithm [29].

Statistical Analysis

To assess the longitudinal trajectory of brain volume and cortical thickness before and after cART in PHI, a piecewise mixed-effects model was applied to the whole brain on a voxel-by-voxel basis. This involved fitting a linear model to the visits before cART initiation, and a different linear model to the visits after cART initiation. Both models were constrained to meet at cART initiation [5]. Age was included as a fixed effect, as well as a participant-specific random intercept.

At the visits before cART initiation in PHI, a multivariable mixed-effects model assessed the relationship between the brain morphometric measures and markers of inflammation, immune status, viral burden, and BBB integrity. This model included age, CD4⁺ and CD8⁺ counts, blood and CSF HIV RNA, and neopterin, CSF WBC, and albumin ratio as fixed effects, and a participant-specific random intercept. Given that NFL was only acquired at enrollment, a fixed-effects model was constructed to assess the correlation of baseline HIV-related factors, including NFL, with baseline brain morphometric measures. All whole-brain statistical maps were corrected for multiple comparisons using the standard false discovery rate with a false-positive rate of 5% [30].

The small HIV-uninfected and CHI groups limited the ability to perform meaningful whole-brain voxel-wise comparisons. Instead, we performed region-of-interest analyses based on prior hypotheses to compare brain volumes and cortical thickness in the PHI group to the HIV-uninfected and CHI groups. Volumes from the thalamus and caudate and cortical thickness from the left and right frontal and temporal lobes were extracted from the enrollment scan in untreated PHI, HIV-uninfected, and CHI participants. These regions were chosen because we demonstrated that they were negatively correlated with duration of untreated infection in the PHI group (see Results and

Figure 1), and we wanted to assess the extent of these structural alterations in the first year of infection relative to the HIV-uninfected and CHI groups. Volumes were also extracted from the putamen, third ventricle, brainstem, and cortical gray matter because these regions were shown to be affected in PHI by previous studies [13–15]. General linear models were used to cross-sectionally compare these measures between the groups, while controlling for age.

RESULTS

Participants

Table 1 summarizes baseline demographic and clinical characteristics of the participants. The PHI group completed a total of 184 MRI scans with a median follow-up duration of 5.0 months (IQR, 0–26.8 months). Treatment was commenced at a median of 6.5 months (IQR, 4.5–16.6 months) after HIV transmission by the 30 treated PHI participants. This resulted in 123 pre-cART scans and 61 post-cART scans. Those who started treatment were significantly older ($P = .04$) and more educated ($P < .001$) at enrollment compared to those who deferred treatment. At enrollment, the median duration of infection after transmission was 3.7 months (IQR, 2.0–5.2 months) in the PHI group, while the CHI participants had a median duration of 90 months since HIV diagnosis, though initial infection date was unknown. HIV-uninfected participants were comparable to the PHI participants with respect to age, sex, and education, whereas CHI participants were only comparable to PHI participants with respect to sex and education.

By the study conclusion, the treated PHI participants had been receiving cART for a median of 7.9 months (IQR, 3.7–29.9 months). Significant improvements in almost all blood and CSF biomarkers ($P < .05$), except albumin ratio, were observed when comparing the first and last MRI visit (Table 2).

A detailed overview of the cART regimens is provided in Supplementary Table 1.

Cross-sectional Comparison of Brain Volumes and Cortical Thickness

Volumes in the thalamus, caudate, putamen, third ventricle, cortical gray matter, and brainstem, and cortical thickness in the temporal and frontal lobes, did not significantly differ between the PHI and HIV-uninfected groups (Table 3). Meanwhile, significant differences in most brain regions were observed when PHI and CHI groups were compared, where CHI participants had smaller brain volumes, thinner cortices, and enlarged third ventricle ($P < .05$).

Brain Volume and Cortical Thickness Changes Prior to cART Initiation in PHI

When brain volume and cortical thickness were estimated by TBM and cortical modeling, respectively, we observed that before cART initiation longer duration of untreated infection was significantly correlated with volume loss in the right

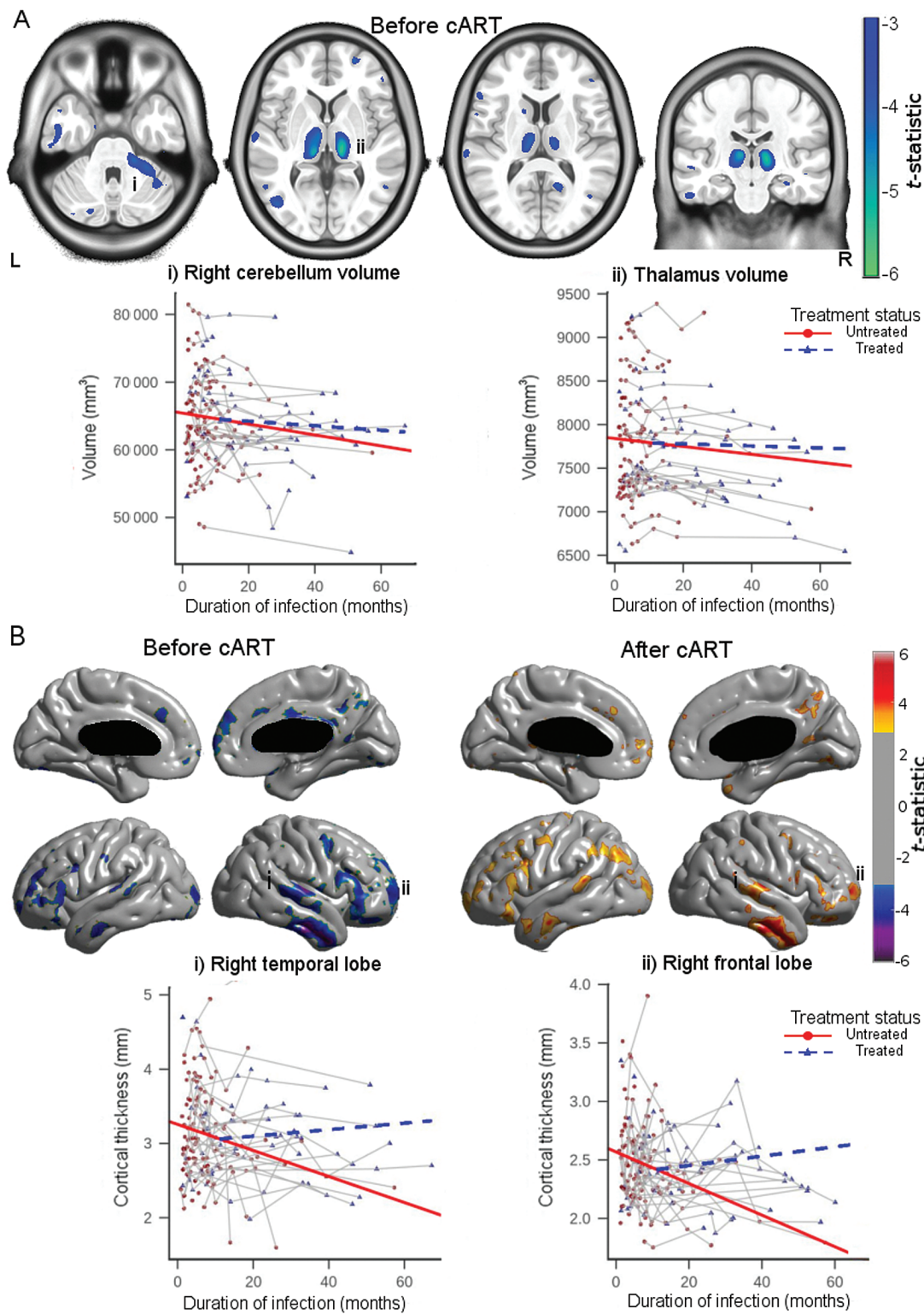


Figure 1. A, Upper row: Brain volume loss associated with longer duration of untreated infection as revealed with tensor-based morphometry. Lower row: Volume of the right cerebellum (left plot) and bilateral thalami (right plot) in relation to the duration of infection. B, Upper row: Cortical thinning associated with longer duration of untreated infection (left) and longer combination antiretroviral therapy (cART) duration (right). Lower row: Cortical thickness of the right superior temporal gyrus (left) and right frontal lobe (right) in relation to the duration of infection for all participants with primary human immunodeficiency virus infection. All brain maps were thresholded at false discovery rate of 5%.

Table 1. Demographic and Clinical Characteristics of Study Participants at Enrollment

Characteristic	HIV Uninfected (n = 19)	Primary HIV Infection (n = 65)	Chronic HIV Infection (n = 16)	P Value ^a	
				PHI vs HIV Uninfected	PHI vs CHI
Age, y, mean (SD)	34.5 (9.9)	36.9 (9.0)	45.1 (10.3)	.36	.01
Sex, male	19 (100)	65 (100)	15 (94)	1.00	.17
Education, y, mean (SD)	16.1 (2.6)	15.4 (2.3)	14.3 (2.3)	.34	.09
Duration of HIV infection, mo median (IQR) ^b	NA	3.7 (2.0–5.2)	90 (48–220)	NA	<.01
CD4 ⁺ T-lymphocyte count, cells/μL, median (IQR)	790 (745–1003)	579 (412–48)	223 (145–310)	<.01	<.01
CD8 ⁺ T-lymphocyte count, cells/μL, median (IQR)	476 (335–732)	901 (641–1151)	1029 (695–1366)	<.01	.50
CD4/CD8 ratio, median (IQR)	1.9 (1.3–2.4)	0.6 (0.4–0.9)	0.2 (0.2–0.3)	<.01	<.01
Blood HIV RNA, log ₁₀ copies/mL, mean (SD)	NA	4.3 (0.9)	4.6 (0.8)	NA	.32
CSF HIV RNA, log ₁₀ copies/mL, mean (SD)	NA	2.5 (0.8)	3.9 (1.1)	NA	<.01
Blood neopterin, nmol/L, median (IQR)	NC	13.0 (7.8–20.4)	18.4 (11.1–22.3)	NA	.13
CSF neopterin, nmol/L, median (IQR)	NC	9.0 (6.6–12.8)	23.9 (19.4–43.6)	NA	<.001
CSF WBC count, cells/μL, mean (SD)	1.8 (1.5)	7.7 (8.3)	8.3 (6.8)	<.01	.80
CSF:albumin ratio, mean (SD)	5.3 (1.9)	5.6 (2.3)	7.6 (3.5)	.60	.05
CSF NFL, pg/mL, median (IQR) ^c	NC	519 (408–793)	NC	NA	NA
History of drug use ^d	6 (86)	49 (77)	13 (87)	.61	.94

Data are presented as No. (%) unless otherwise indicated.

Abbreviations: CHI, chronic human immunodeficiency virus infection; CSF, cerebrospinal fluid; HIV, human immunodeficiency virus; IQR, interquartile range; NA, not applicable; NC, not collected; NFL, neurofilament light chain; PHI, primary human immunodeficiency virus infection; SD, standard deviation; WBC, white blood cell.

^aComparisons were made using Wilcoxon signed-rank test for continuous variables and χ^2 test for categorical variables.

^bDuration of HIV infection for PHI was estimated by date of recent seroconversion as confirmed by laboratory measures. CHI duration of infection reflects the period since known HIV diagnosis.

^cCSF NFL only measured in PHI participants at baseline.

^dHistory of drug use was unknown for 12 HIV-uninfected, 1 PHI, and 1 CHI participants.

cerebellum, bilateral thalami, left caudate, and left temporal lobe ($P < .05$; [Figure 1A](#)), and with cortical thinning in bilateral frontal and temporal lobes, and cingulate cortex ($P < .05$; [Figure 1B](#)). Within these regions, the median atrophy rate was 0.63% per year (IQR, 0.55%–0.73% per year; [Supplementary Figure 1](#)), and the median cortical thinning rate was 0.25 mm/year (IQR, 0.22–0.30 mm/year; [Supplementary Figure 2](#)).

Brain Volume and Cortical Thickness Changes After cART Initiation in PHI
After cART, no further brain volume loss or cortical thinning was observed. However, small but significant increases of cortical thickness in the right frontal and temporal lobes ($P < .05$) and trend-level thickness increases in the left frontal and temporal lobes ($P < .1$) were correlated with longer cART duration ([Figure 1B](#)).

Table 2. Comparison of First and Last Magnetic Resonance Imaging Visit in the Primary Human Immunodeficiency Virus Infection Participants Who Initiated Combination Antiretroviral Therapy

Laboratory Test	First Visit (n = 29) ^a	Last Visit (n = 29) ^a	Difference Between Visits (95% CI)	P Value ^b
CD4 ⁺ T-lymphocyte count, cells/μL, median (IQR)	441 (372–628)	531 (469–758)	89 (26–176)	.004
CD8 ⁺ T-lymphocyte count, cells/μL, median (IQR)	881 (619–1142)	693 (574–914)	–225 (–379 to –60)	.004
CD4/CD8 ratio, median (IQR)	0.5 (0.4–0.9)	0.9 (0.6–1.1)	0.3 (.2–.4)	<.001
Blood HIV RNA, log ₁₀ copies/mL, mean (SD)	4.4 (1.0)	1.8 (0.6)	–2.6 (–3.1 to –2.1)	<.001
CSF HIV RNA, log ₁₀ copies/mL, mean (SD)	2.7 (0.7)	1.7 (0.2)	–1.0 (–1.3 to –.6)	<.001
Blood neopterin, nmol/L, median (IQR)	11.5 (8.0–21.0)	6.2 (4.6–9.0)	–7.5 (–11.2 to –3.5)	<.001
CSF neopterin, nmol/L, median (IQR)	9.0 (6.8–11.6)	7.1 (5.2–9.5)	–2.0 (–7.5 to .3)	.07
CSF WBC count, cells/μL, mean (SD)	7.7 (6.4)	3.3 (4.4)	–3.8 (–7.8 to –.1)	.03
CSF:albumin ratio, mean (SD)	5.8 (1.9)	5.5 (1.9)	–0.22 (–1.1 to .6)	.54

Abbreviations: CI, confidence interval; CSF, cerebrospinal fluid; HIV, human immunodeficiency virus; IQR, interquartile range; SD, standard deviation; WBC, white blood cell.

^aOne subject who initiated treatment only had 1 visit.

^bP value calculated using Wilcoxon signed-rank test for paired samples (CD4⁺ and CD8⁺ cell counts, CD4/CD8 ratio, albumin ratio, and CSF WBC count) and paired *t* test (blood and CSF HIV RNA).

Table 3. Cross-sectional Comparison of Brain Volumes at Baseline

Brain Area	HIV Uninfected, Mean (SD)	PHI, Mean (SD)	CHI, Mean (SD)	P Value ^a	
				PHI vs HIV Uninfected	PHI vs CHI
Thalamus ^b , mm ³	7663.0 (877.2)	7816.0 (661.0)	7108.3 (954.2)	.25	.02
Caudate ^b , mm ³	5871.8 (666.9)	5744.7 (598.6)	5215.0 (435.0)	.61	.03
Putamen ^b , mm ³	5395.9 (531.7)	5188.4 (494.0)	4661.2 (688.1)	.22	.07
Third ventricle, mm ³	1513.5 (491.2)	1691.5 (521.9)	2310.1 (1054.8)	.28	.03
Brainstem, mm ³	33899.7 (3792.3)	34895.8 (3408.7)	32755.4 (3335.7)	.31	.06
Cortical gray matter, mm ³	609920 (73996.8)	616862 (60774.6)	558856 (71997.4)	.71	.008
Superior temporal lobe ^c , mm	2.8 (0.5)	2.7 (0.3)	2.4 (0.6)	.77	.07
Frontal lobe ^c , mm	2.9 (0.6)	2.9 (0.4)	2.5 (0.6) ^d	.87	.02

Abbreviations: CHI, chronic human immunodeficiency virus infection; HIV, human immunodeficiency virus; PHI, primary human immunodeficiency virus infection; SD, standard deviation.

^aP values calculated from a general linear model while controlling for age.

^bVolumes from the left and right hemisphere were averaged.

^cCortical thickness from the left and right hemisphere were averaged.

^dOne CHI participant was considered an outlier and removed because cortical thickness was >5.9σ.

Brain Volume and Cortical Thickness Correlations With Blood and CSF Measures in Untreated PHI

The relationship between brain morphometrics and blood and CSF measures were tested during untreated visits in PHI participants. Increasing CSF HIV RNA tended to be correlated with volume loss in the thalamus ($P < .1$), while CD4⁺ count was positively correlated with cortical thickness in the left frontal lobe ($P < .1$). However, these correlations did not reach statistical significance after multiple comparisons correction. The remaining blood and CSF measures, including NFL, were not significantly associated with any brain morphometric measures.

DISCUSSION

While several studies have investigated the effects of HIV on the brain in early infection, the natural course of structural changes that occur during this period and the impact cART has on these changes are not completely characterized. We observed that before cART initiation, PHI participants experienced progressive atrophy and cortical thinning that worsened with the absence of treatment. However, after cART was commenced, no further structural deterioration was observed.

We demonstrated that, during untreated infection, PHI participants had a median atrophy and thinning rate of 0.63% per year and 0.25 mm per year, respectively. These rates were of greater magnitude than that of normal aging, with previous studies reporting atrophy rates of 0.2% per year [31] and thinning rates of 0.01 mm per year [32] in similarly aged healthy individuals. This suggests that untreated PHI individuals may experience greater-than-age-related brain changes. However, given that longitudinal control data was not acquired, we cannot definitively conclude that the observed atrophy is a result of the infection. Future longitudinal studies are warranted to clarify whether structural atrophy is caused by the virus or confounded by ageing.

These findings, along with reports from previous studies [5, 7–9, 11, 12, 16], support the presumed initiation of HIV neuropathogenesis in early infection. The virus penetrates the CNS after initial systemic viral infection, infecting and activating local CNS immune cells [1]. These cells begin to release viral proteins and produce inflammatory factors, resulting in prominent inflammation [5–7], immune activation and suppression [8–10], and BBB disruption [11], all of which facilitate neuronal injury and brain volume reduction [1, 12, 13, 15]. If the infection remains untreated, we demonstrate here that brain atrophy and cortical thinning continues, while others report that markers of immune status, inflammation, and BBB permeability progressively worsen [5, 9, 11]. Although the observed atrophy was not associated with any blood or CSF biomarkers, this could be an indication that a single biomarker is insufficient to infer underlying structural brain alterations; instead, a combination of these biomarkers may be more suitable for neurological prognosis.

The brain regions affected during untreated infection correspond with previous studies that examined people living with HIV. These studies reported volume reductions throughout the subcortical regions [2, 3, 33–36] and cerebellum [37, 38], and cortical thickness reductions in the frontal and temporal lobes and the cingulate cortex [2, 3, 17, 39]. The data in aggregate add to the growing body of evidence that demonstrate the brain is not spared in early infection. This suggests that the brain volume reductions reported in people living with HIV may reflect changes that occurred, in part, during untreated infection.

In the subset of PHI participants who commenced cART, we observed improvements in markers of inflammation, immune status, and viral burden. While this is not surprising, given that cART has been successful in treating systemic HIV infection, the impact it has on the brain is less known. Here, we did not find brain atrophy nor cortical thinning after cART initiation. Notably, we did not observe further brain changes with TBM.

This is worth noting because while this suggests that treatment prevents further atrophy, it points to possible permanent and irreversible changes. Interestingly, small increases in cortical thickness were found in the frontal and temporal lobes, suggesting that cortical volume partially recovers with treatment. However, extra caution must be exercised when interpreting these results; considering that 30 PHI participants started cART, yielding 61 post-cART scans, the likelihood of false-positive errors increases. Nonetheless, the findings were consistent with a previous magnetic resonance spectroscopy (MRS) study performed in acute HIV, where increased *N*-acetylaspartate in the frontal gray and white matter was associated with cART [7]. Potential neural repair mechanisms have been investigated in HIV, where neurotrophic factors, such as macrophage inflammatory protein 2 [40], released from local immune cells could stimulate neuronal regeneration [1]. However, it remains unknown if these mechanisms contribute to cortical thickness recovery. It is also possible that neuroinflammation from cART could cause cortical thickness increases, but an MRS study conducted on the same PHI group reported that the choline-to-creatinine ratio in the frontal lobe decreased after cART initiation, possibly reflecting attenuated neuroinflammation after cART. This suggests that neuroinflammation may be an unlikely contributor of cortical thickness increase [5]. In any case, our findings suggest that cART could arrest structural atrophy, emphasizing the importance of early treatment.

To further assess the existence and extent of brain changes in PHI, we extracted volumes from the thalamus, caudate, putamen, third ventricle, cortical gray matter and brainstem, and cortical thickness from the temporal and frontal lobes from each group. In contrast to previous PHI work [13–15], the brain regions were not significantly different in the PHI group compared to the HIV-uninfected group. Discrepancies with prior studies reflect differences in sample size [14, 15], duration of untreated infection [13, 14], number of cART-treated participants [13, 14], and the brain regions investigated [13–15].

As expected, the untreated CHI group had smaller brain volumes, thinner cortices, and enlarged third ventricle compared to PHI. While this result is not surprising, considering that the CHI group had been infected for a median of 90 months and most participants were cART-naïve, we cannot rule out group differences contributing to these results. Taken together, these findings provide further insight into the natural course of brain volume changes in PHI, where macroscopic changes as seen on MRI in the investigated brain regions may not be detectable after a median time of 3.7 months of infection. Meanwhile, the CHI group consistently had worse brain volume and cortical thickness measures. Presumably, brain volumes in the PHI group would approach the volumes observed in the CHI group with continued absence of treatment. Although causal inferences cannot be made with cross-sectional data, these conclusions are supported by our longitudinal data; altogether, the data provide

additional suggestive evidence for brain atrophy progressing in the absence of treatment, arguing for early treatment.

This study has limitations. First, the HIV-uninfected and CHI groups were small, limiting the ability to perform exploratory whole-brain voxel-wise statistics and reducing the generalizability. Second, because longitudinal data on controls and CHI participants were not acquired, we cannot determine when the structural brain changes begin to occur or estimate any component related to aging. Third, given that data on lifestyle were not acquired, we cannot definitively exclude that lifestyle modifications after cART initiation contributes to the post-cART results. Finally, the study participants were young adult men with a history of drug use, limiting the generalizability of the results to individuals with similar characteristics.

In conclusion, our findings provide a unique narrative regarding the natural course of brain volume changes in early HIV infection. We reported that atrophy and cortical thinning begins early in infection, principally during untreated infection, and worsens with the continued absence of cART. However, initiating cART may halt further structural deterioration, emphasizing the importance of early cART.

Supplementary Data

Supplementary materials are available at *Clinical Infectious Diseases* online. Consisting of data provided by the authors to benefit the reader, the posted materials are not copyedited and are the sole responsibility of the authors, so questions or comments should be addressed to the corresponding author.

Notes

Acknowledgments. The authors are grateful to the participants who volunteered for these studies and the staff at the UCSF Options Study and Magnet/San Francisco AIDS Foundation for collaboration and referral of study participants.

Financial support. This work was supported by the Natural Sciences and Engineering Research Council (award number PGSD3-489934 to R. S.) and by the National Institute of Mental Health (grant numbers R01MH081772, K23 MH074466, and R21MH099979 to S. S. and B. M. A.).

Potential conflicts of interest. All authors: No reported conflicts of interest. All authors have submitted the ICMJE Form for Disclosure of Potential Conflicts of Interest. Conflicts that the editors consider relevant to the content of the manuscript have been disclosed.

References

- González-Scarano F, Martín-García J. The neuropathogenesis of AIDS. *Nat Rev Immunol* 2005; 5:69–81.
- Sanford R, Fernandez Cruz AL, Scott SC, et al. Regionally specific brain volumetric and cortical thickness changes in HIV-infected patients in the HAART Era. *J Acquir Immune Defic Syndr* 2017; 74:563–70.
- Sanford R, Fellows LK, Ances BM, Collins DL. Association of brain structure changes and cognitive function with combination antiretroviral therapy in HIV-positive individuals. *JAMA Neurol* 2018; 75:72–9.
- Cole JH, Caan MWA, Underwood J, et al. No evidence for accelerated ageing-related brain pathology in treated HIV: longitudinal neuroimaging results from the comorbidity in relation to AIDS (COBRA) project [manuscript published online ahead of print 4 January 2018]. *Clin Infect Dis* 2018; 66:1189–909.
- Young AC, Yiannoutsos CT, Hegde M, et al. Cerebral metabolite changes prior to and after antiretroviral therapy in primary HIV infection. *Neurology* 2014; 83:1592–600.
- Valcour V, Chalermchai T, Sailasuta N, et al; RV254/SEARCH 010 Study Group. Central nervous system viral invasion and inflammation during acute HIV infection. *J Infect Dis* 2012; 206:275–82.

7. Sailasuta N, Ross W, Ananworanich J, et al; RV254/SEARCH 010 Protocol Teams. Change in brain magnetic resonance spectroscopy after treatment during acute HIV infection. *PLoS One* **2012**; 7:e49272.
8. Spudich S, Gisslen M, Hagberg L, et al. Central nervous system immune activation characterizes primary human immunodeficiency virus 1 infection even in participants with minimal cerebrospinal fluid viral burden. *J Infect Dis* **2011**; 204:753–60.
9. Suh J, Sinclair E, Peterson J, et al. Progressive increase in central nervous system immune activation in untreated primary HIV-1 infection. *J Neuroinflammation* **2014**; 11:1–8.
10. Kessing CF, Spudich S, Valcour V, et al. High number of activated CD8+ T Cells targeting HIV antigens are present in cerebrospinal fluid in acute HIV infection. *J Acquir Immune Defic Syndr* **2017**; 75:108–17.
11. Rahimy E, Li FY, Hagberg L, et al. Blood-brain barrier disruption is initiated during primary HIV infection and not rapidly altered by antiretroviral therapy. *J Infect Dis* **2017**; 215:1132–40.
12. Peluso MJ, Meyerhoff DJ, Price RW, et al. Cerebrospinal fluid and neuroimaging biomarker abnormalities suggest early neurological injury in a subset of individuals during primary HIV infection. *J Infect Dis* **2013**; 207:1703–12.
13. Ragin AB, Du H, Ochs R, et al. Structural brain alterations can be detected early in HIV infection. *Neurology* **2012**; 79:2328–34.
14. Ragin AB, Wu Y, Gao Y, et al. Brain alterations within the first 100 days of HIV infection. *Ann Clin Transl Neurol* **2015**; 2:12–21.
15. Wright PW, Pyakurel A, Vaida FF, et al. Putamen volume and its clinical and neurological correlates in primary HIV infection. *AIDS* **2016**; 30:1789–94.
16. Kelly SG, Taiwo BO, Wu Y, et al. Early suppressive antiretroviral therapy in HIV infection is associated with measurable changes in the corpus callosum. *J Neurovirol* **2014**; 20:514–20.
17. Thompson PM, Dutton RA, Hayashi KM, et al. Thinning of the cerebral cortex visualized in HIV/AIDS reflects CD4+ T lymphocyte decline. *Proc Natl Acad Sci U S A* **2005**; 102:15647–52.
18. Cardenas VA, Meyerhoff DJ, Studholme C, et al. Evidence for ongoing brain injury in human immunodeficiency virus-positive patients treated with antiretroviral therapy. *J Neurovirol* **2009**; 15:324–33.
19. Zetola NM, Pilcher CD. Diagnosis and management of acute HIV infection. *Infect Dis Clin North Am* **2007**; 21:19–48, vii.
20. Spudich SS, Nilsson AC, Lollo ND, et al. Cerebrospinal fluid HIV infection and pleocytosis: relation to systemic infection and antiretroviral treatment. *BMC Infect Dis* **2005**; 5:98.
21. Aubert-Broche B, Fonov VS, García-Lorenzo D, et al. A new method for structural volume analysis of longitudinal brain MRI data and its application in studying the growth trajectories of anatomical brain structures in childhood. *Neuroimage* **2013**; 82:393–402.
22. Sled JG, Zijdenbos AP, Evans AC. A nonparametric method for automatic correction of intensity nonuniformity in MRI data. *IEEE Trans Med Imaging* **1998**; 17:87–97.
23. Eskildsen SF, Coupé P, Fonov V, et al; Alzheimer's Disease Neuroimaging Initiative. BEaST: brain extraction based on nonlocal segmentation technique. *Neuroimage* **2012**; 59:2362–73.
24. Collins DL, Neelin P, Peters TM, Evans AC. Automatic 3D intersubject registration of MR volumetric data in standardized Talairach space. *J Comput Assist Tomogr* **1994**; 18:192–205.
25. Fonov V, Evans AC, Botteron K, Almli CR, McKinstry RC, Collins DL; Brain Development Cooperative Group. Unbiased average age-appropriate atlases for pediatric studies. *Neuroimage* **2011**; 54:313–27.
26. Collins DL, Holmes CJ, Peters TM, Evans AC. Automatic 3-D model-based neuroanatomical segmentation. *Hum Brain Mapp* **1995**; 3:190–208.
27. Ashburner J, Friston KJ. Voxel-based morphometry—the methods. *Neuroimage* **2000**; 11:805–21.
28. Eskildsen SF, Ostergaard LR. Active surface approach for extraction of the human cerebral cortex from MRI. *Med Image Comput Comput Assist Interv* **2006**; 9:823–30.
29. Järnum H, Eskildsen SF, Steffensen EG, et al. Longitudinal MRI study of cortical thickness, perfusion, and metabolite levels in major depressive disorder. *Acta Psychiatr Scand* **2011**; 124:435–46.
30. Genovese CR, Lazar NA, Nichols T. Thresholding of statistical maps in functional neuroimaging using the false discovery rate. *Neuroimage* **2002**; 15:870–8.
31. Fox NC, Schott JM. Imaging cerebral atrophy: normal ageing to Alzheimer's disease. *Lancet* **2004**; 363:392–4.
32. Pacheco J, Goh JO, Kraut MA, Ferrucci L, Resnick SM. Greater cortical thinning in normal older adults predicts later cognitive impairment. *Neurobiol Aging* **2015**; 36:903–8.
33. Chiang MC, Dutton RA, Hayashi KM, et al. 3D pattern of brain atrophy in HIV/AIDS visualized using tensor-based morphometry. *Neuroimage* **2007**; 34:44–60.
34. Becker JT, Sanders J, Madsen SK, et al; Multicenter AIDS Cohort Study. Subcortical brain atrophy persists even in HAART-regulated HIV disease. *Brain Imaging Behav* **2011**; 5:77–85.
35. Ances BM, Ortega M, Vaida F, Heaps J, Paul R. Independent effects of HIV, aging, and HAART on brain volumetric measures. *J Acquir Immune Defic Syndr* **2012**; 59:469–77.
36. Kallianpur KJ, Shikuma C, Kirk GR, et al. Peripheral blood HIV DNA is associated with atrophy of cerebellar and subcortical gray matter. *Neurology* **2013**; 80:1792–9.
37. Klunder AD, Chiang MC, Dutton RA, et al. Mapping cerebellar degeneration in HIV/AIDS. *Neuroreport* **2008**; 19:1655–9.
38. Clifford KM, Samboju V, Cobigo Y, et al. Progressive brain atrophy despite persistent viral suppression in HIV patients older than 60 years. *J Acquir Immune Defic Syndr* **2017**; 76:289–97.
39. Kallianpur KJ, Kirk GR, Sailasuta N, et al. Regional cortical thinning associated with detectable levels of HIV DNA. *Cereb Cortex* **2012**; 22:2065–75.
40. Kalehua AN, Nagel JE, Whelchel LM, et al. Monocyte chemoattractant protein-1 and macrophage inflammatory protein-2 are involved in both excitotoxicity-induced neurodegeneration and regeneration. *Exp Cell Res* **2004**; 297:197–211.