

## Scar undone: long-term therapy of hepatitis B



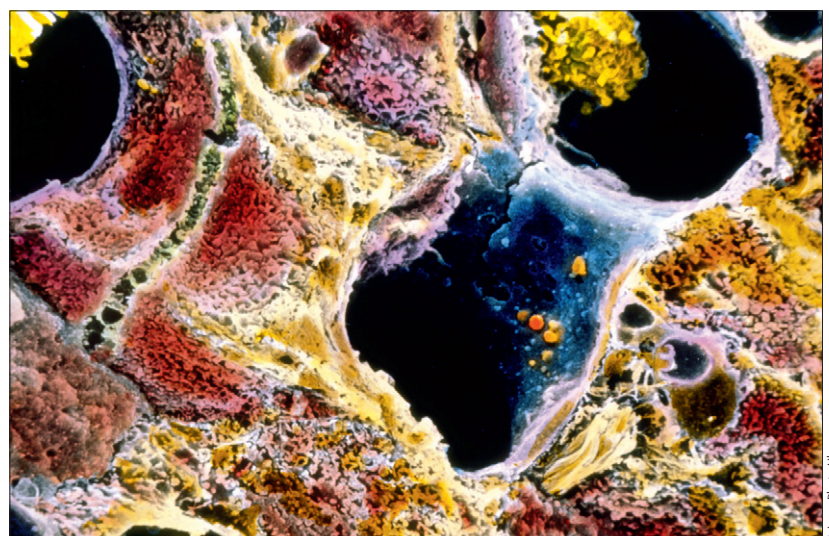
In recent years, substantial progress has been made in the prevention and control of hepatitis B, a major cause of chronic liver disease, cirrhosis, and liver cancer worldwide.<sup>1</sup> A safe and effective hepatitis B virus vaccine was developed in the early 1980s, and its subsequent widespread use resulted in notable decreases in rates of hepatitis B, at least in countries that adopted universal hepatitis B vaccination.<sup>2</sup> Therapies for hepatitis B were developed more recently and are only now showing an effect on the burden of this disease. Interferon alfa was approved for this indication in the USA in 1991, but had low efficacy and was not well tolerated.<sup>3</sup> Oral antiviral agents with activity against hepatitis B were developed in the 1990s. The first three agents approved in the USA (lamivudine in 1998, adefovir in 2002, and telbivudine in 2006) were very well tolerated, and yielded good viral suppression and clinical responses in 1–2 year studies.<sup>4,5</sup> With more prolonged therapy, however, the efficacy of these agents was limited by antiviral resistance.<sup>6</sup> These shortcomings seem to be overcome by two newer, more potent antiviral agents—entecavir (approved in 2005) and tenofovir disoproxil fumarate (approved in 2008)—both of which have a high barrier to antiviral resistance. These antiviral agents suppress serum hepatitis B virus DNA to near or below detectable levels, and result in high rates of improvement in both biochemical and histological evidence of disease.<sup>7</sup> Studies show that their long-term use (3–5 years) maintains viral suppression and biochemical improvements.<sup>8,9</sup>

In this issue of *The Lancet*, Patrick Marcellin and colleagues<sup>10</sup> report that long-term therapy also leads to substantial histological improvements, including decreases in fibrosis and apparent regression of cirrhosis. Such effects of long-term antiviral therapy of hepatitis B (and C and D) have been reported previously, but no other report has been as large or convincing.<sup>8,11,12</sup> In 489 patients with chronic hepatitis B treated with tenofovir for 4–5 years, 348 underwent repeat liver biopsy. Liver histology showed improvement in inflammation and necrosis in almost all patients and a decrease in fibrosis in 51% (176 of 348 patients). An impressive finding was an apparent regression of cirrhosis in 74% of those with cirrhosis on initial biopsy (71 of 96 patients). Patients without resolution of cirrhosis were more likely to be overweight or obese.

Regression of fibrosis, as shown by paired liver biopsies before and after 4 years of therapy, is a strong and convincing endpoint in support of treatment. Nevertheless, histological improvement is a surrogate endpoint for the clinical consequences of cirrhosis: clinical decompensation, death from end-stage liver disease, and hepatocellular carcinoma, the dreaded long-term complication of chronic hepatitis B. In the study from Marcellin and colleagues, these hard endpoints were apparently improved but less well documented than the histological changes. The rate of hepatocellular carcinoma was about 2% (12 cases). Importantly, in patients without hepatocellular carcinoma, none developed hepatic compensation or died of end-stage liver disease. The study did not include an untreated control group for obvious reasons, but historical controls would have predicted higher rates for both outcomes.<sup>13</sup> This study and many others now support the recommendation that patients with chronic hepatitis B receive long-term treatment with a potent oral antiviral agent with a high barrier to resistance.

If long-term treatment is recommended, how long should it be continued for, and what criteria should be used to decide when to stop therapy? In patients with HBeAg-positive hepatitis B, guidelines recommend discontinuation of antiviral therapy 6 months after loss of HBeAg. Furthermore, in patients with HBeAg-negative disease, findings from case series have shown that

Published Online  
December 10, 2012  
[http://dx.doi.org/10.1016/S0140-6736\(12\)61721-8](http://dx.doi.org/10.1016/S0140-6736(12)61721-8)  
See Online/Articles  
[http://dx.doi.org/10.1016/S0140-6736\(12\)61425-1](http://dx.doi.org/10.1016/S0140-6736(12)61425-1)



**Liver cirrhosis**  
Coloured scanning electron micrograph showing phagocytes (yellow) in blood vessels (blue).

treatment can be safely discontinued after 3–5 years of treatment in some patients.<sup>14</sup> In Marcellin and colleagues' study,<sup>10</sup> tenofovir was continued anyway. Certainly, the loss of HBsAg, either with or without development of anti-HBs, is a signal that treatment can be stopped (as was shown in the 12 patients who stopped treatment and continued in this study). However, this endpoint was not especially common, since it occurred in only 23 of the 489 patients after 5 years of treatment.

The possible disadvantages of long-term therapy must be considered. An important issue for our overburdened health-care systems is cost: the suggested wholesale prices of tenofovir and entecavir are US\$11304 and \$13212 every year for the drugs alone.

The safety of long-term nucleoside therapy is also a consideration. Multiple case reports and small case series have documented that tenofovir can cause renal proximal tubular dysfunction, similar to Fanconi syndrome.<sup>15</sup> Abnormalities usually develop after several years of treatment and are characterised by phosphate-wasting nephropathy and mild renal insufficiency. Typically, serum phosphate (and uric acid) concentrations decrease, serum creatinine increases minimally (by 18–44 µmol/L), and mild proteinuria develops (mostly low-molecular-weight proteins such as β-2-microglobulin). Complete renal failure is rare, but hypophosphataemia can be severe, symptomatic, and even life threatening. In severe cases, osteomalacia or renal tubular acidosis can occur.<sup>16</sup>

Thus, efficacious long-term therapy with potent oral antiviral agents is an important advance for the management of chronic hepatitis B, but challenges remain. Which patients should be treated, for how long, and to what clinical endpoint? How can the rate of HBsAg loss be increased and the persistent risk of hepatocellular carcinoma be reduced? What is the safety of long-term therapy and how should patients be monitored? Good clinical studies often pose more

questions than they can answer, and the accompanying study by Marcellin and colleagues is no exception.

Michele M Tana, \*Jay H Hoofnagle

Liver Diseases Branch, Division of Intramural Research, National Institute of Diabetes and Digestive and Kidney Diseases, National Institutes of Health, Bethesda, MD 20892, USA  
hoofnaglej@extra.niddk.nih.gov

We declare that we have no conflicts of interest.

- 1 WHO. Hepatitis B: fact sheet no. 204. July, 2012. <http://www.who.int/mediacentre/factsheets/fs204/en/> (accessed Sept 17, 2012).
- 2 Kim WR. Epidemiology of hepatitis B in the United States. *Hepatology* 2009; **49** (suppl 5): S28–34.
- 3 Müller R, Baumgarten R, Markus R, et al. Treatment of chronic hepatitis B with interferon alfa-2b. *J Hepatol* 1990; **11** (suppl 1): S137–40.
- 4 Lai CL, Chien RN, Leung NW, et al, for the Asia Hepatitis Lamivudine Study Group. A one-year trial of lamivudine for chronic hepatitis B. *N Engl J Med* 1998; **339**: 61–68.
- 5 Marcellin P, Chang TT, Lim SG, et al. Adefovir dipivoxil for the treatment of hepatitis B e antigen-positive chronic hepatitis B. *N Engl J Med* 2003; **348**: 808–16.
- 6 Ghany MG, Doo EC. Antiviral resistance and hepatitis B therapy. *Hepatology* 2010; **49** (5 suppl): S174–84.
- 7 Chang TT, Gish RG, de Man R, et al. A comparison of entecavir and lamivudine for HBeAg-positive chronic hepatitis B. *N Engl J Med* 2006; **354**: 1001–10.
- 8 Chang TT, Liaw YF, Wu SS, et al. Long-term entecavir therapy results in the reversal of fibrosis/cirrhosis and continued histological improvement in patients with chronic hepatitis B. *Hepatology* 2010; **52**: 886–93.
- 9 Heathcote EJ, Marcellin P, Buti M, et al. Three-year efficacy and safety of tenofovir disoproxil fumarate treatment for chronic hepatitis B. *Gastroenterology* 2011; **140**: 132–43.
- 10 Marcellin P, Gane E, Buti M, et al. Regression of cirrhosis during treatment with tenofovir disoproxil fumarate for chronic hepatitis B: a 5-year open-label follow-up study. *Lancet* 2012; published online Dec 10. [http://dx.doi.org/10.1016/S0140-6736\(12\)61425-1](http://dx.doi.org/10.1016/S0140-6736(12)61425-1).
- 11 Lau DT, Kleiner DE, Park Y, Di Bisceglie AM, Hoofnagle JH. Resolution of chronic delta hepatitis after 12 years of interferon alpha therapy. *Gastroenterology* 1999; **117**: 1229–33.
- 12 Marcellin P, Boyer N, Gervais A, et al. Long-term histologic improvement and loss of detectable intrahepatic HCV RNA in patients with chronic hepatitis C and sustained response to interferon-alpha therapy. *Ann Intern Med* 1997; **127**: 875–81.
- 13 Liaw YF, Sung JJ, Chow WC, et al. Lamivudine for patients with chronic hepatitis B and advanced liver disease. *N Engl J Med* 2004; **351**: 1521–31.
- 14 Hadziyannis SJ, Sevilian V, Rapti I, Vassilopoulos D, Hadziyannis E. Sustained responses and loss of HBsAg in HBeAg-negative patients with chronic hepatitis B who stop long-term treatment with adefovir. *Gastroenterology* 2012; **143**: 629–36.e1.
- 15 Gara N, Zhao X, Collins MT, et al. Renal tubular dysfunction during long-term adefovir or tenofovir therapy in chronic hepatitis B. *Aliment Pharmacol Ther* 2012; **35**: 1317–25.
- 16 Gupta SK. Tenofovir-associated Fanconi syndrome: review of the FDA adverse event reporting system. *AIDS Patient Care STDS* 2008; **22**: 99–103.