Second clinical episode of hMPX virus in a man having sex with men

Jeremy Zeggagh, Olivier Ferraris, Maud Salmona, Arnaud Tarantola, Jean-Michel Molina, Constance Delaugerre

Lancet 2023; 401: 1610

Published Online March 24, 2023 https://doi.org/10.1016/S0140-6736(23)00509-3

Service de Maladies Infectieuses, Hôpital Saint-Louis, AP–HP, Paris, France (J Zeggagh MD, Prof J-M Molina MD); **CNR-LE – Orthopoxvirus, Institut de Recherche Biomédicale des Armées, Brétigny-sur-Orge, France** (O Ferraris PhD); **Service de Virologie, Hôpital Saint-Louis, AP–HP, Paris, France** (M Salmona PhD, Prof C Delaugerre PhD); **INSERM Equipe INSIGHT, U976, Université Paris Cité, Paris, France** (M Salmona); **Direction des Régions, Santé Publique France, Saint-Maurice, France** (A Tarantola PhD); **INSERM U944, Université Paris Cité, Paris, France** (Prof J-M Molina, Prof C Delaugerre)

Correspondence to: Prof Constance Delaugerre, Service de Virologie, Hôpital Saint-Louis, AP–HP, Paris 75475, France **constance.delaugerre@aphp.fr**

See Online for appendix

A 36-year-old man attended our hospital with an 8-day history of two vesiculopustular lesions on his penis (figure); he reported no fever or inguinal lymphadenopathy. The patient had no previous history of note; he had not been immunised against smallpox. Over the past 3 years he said that he regularly took pre-exposure prophylaxis (PrEP) against HIV.

4 weeks before the lesions appeared, the patient reported having condomless penetrative and receptive anal intercourse with approximately 30 male partners. None of his known partners had notified him of having developed similar symptoms.

On examination he was well; his temperature was 38·0°C. PCR of a sample of one of the penile lesions confirmed human monkeypox (hMPX) virus infection: MPX-virus PCR cycle threshold (Ct) 20·5. Tests for bacterial sexually transmitted infections—including gonorrhoea, chlamydia, and syphilis—were negative on oral, anal, and urine samples. The patient was isolated at home for 3 weeks and was prescribed symptomatic treatment for pain. During isolation, he experienced no other symptoms, but developed additional vesicular lesions on his trunk and upper and lower limbs. The course of the disease was uneventful, and all lesions disappeared completely within 30 days. In accordance with French recommendations, the patient was not vaccinated.

97 days after the first consultation, 50 vesicular lesions, associated with very painful inguinal lymphadenopathy, developed over 24 h on the patient's penis (figure); he reported no prodromal symptoms. 2 days later, he developed an influenza-like illness with a fever—temperature 38·5°C—fatigue, myalgias, and headache; the symptoms resolved spontaneously 9 days after onset. Laboratory investigations showed negative HIV serology and HIV-1 RNA PCR was less than 20 copies per mL, but immunoglobulin G against hepatitis A and hepatitis B, Epstein-Barr virus, and cytomegalovirus were positive. PCR on a sample from a penile swab was negative for herpes simplex virus types 1 and 2, and varicella zoster virus, although a concurrent pharyngeal gonorrhoea infection was found. Two hMPX virus PCRs on samples of cutaneous swabs obtained at the second-episode consultation (Ct 30·3) and 7 days later (Ct 33·21) confirmed the diagnosis. During the month preceding the second episode, the patient reported having unprotected sex with approximately 50 male partners from European countries, where he had attended mass gatherings and sex parties. Facing a potential hMPX reinfection, neutralising antibodies against the hMPX virus (appendix) were measured; the titers were weakly positive (index 20·3) and abnormally low for a person with a documented hMPX virus infection 3 months earlier. Samples from both the first and second episodes were whole-genome hMPX virus sequenced (appendix) and the isolates were found to belong to hMPX virus subtype IIb, lineage B.1, which has been previously described in the European outbreak. Comparisons between the sequences from the different episodes showed the viruses differed at 14 single nucleotides, one DNA sequence insertion, and one DNA sequence deletion (appendix). Phylogenetic analysis clustered the two sequences together (bootstrap value 95%).

In conclusion, we believe our patient was reinfected with a different hMPX. Vaccination may be considered on a case-by-case basis for people at very high risk of repeatedly contracting the disease.

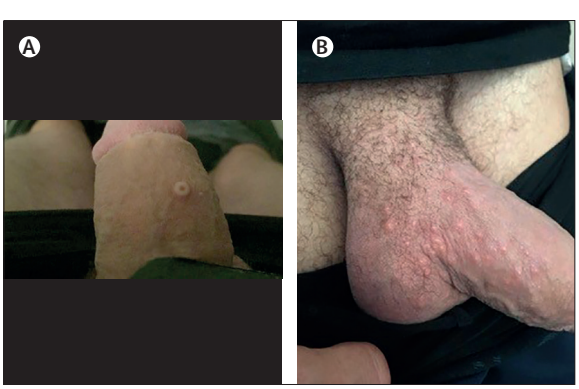

Figure: **Second clinical episode of hMPX virus in a man having sex with men**
(A) Photo shows a vesiculopustular penile lesion found at presentation with initial infection. (B) Photo shows multiple vesicular lesions on the penis found at presentation of the second infection 97 days later.

Contributors
JZ and CD were involved in the management, diagnosis, and care of the patient. OF, MS, and CD were responsible for the virology. We all reviewed and revised the manuscript. Written consent for publication was obtained from the patient.

Declaration of interests
We declare no competing interests.

Acknowledgments
We would like to thank Le 190 for trusting us with the care of their patient.

Copyright © 2023 Elsevier Ltd. All rights reserved.